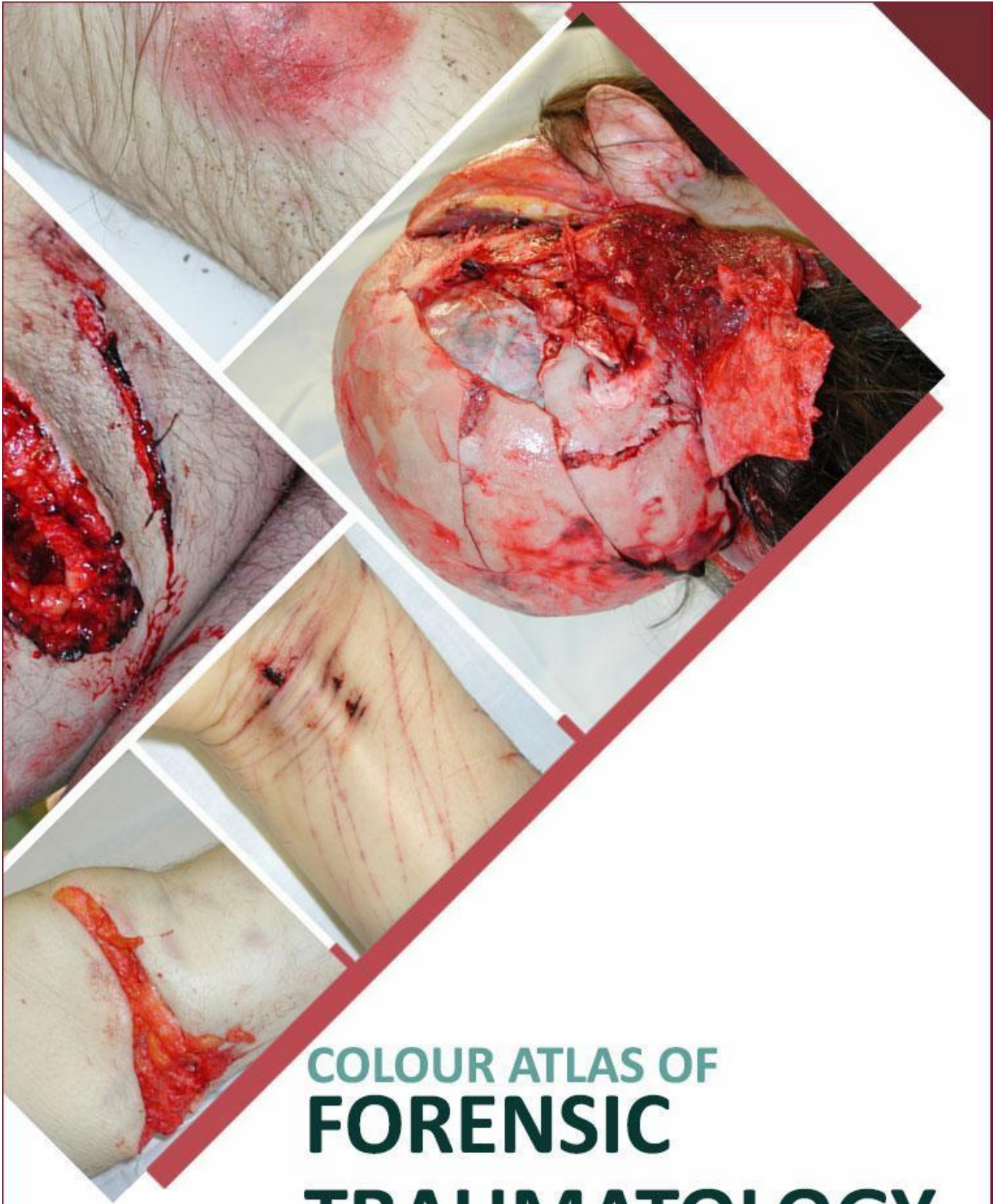



COLOUR ATLAS OF
FORENSIC
TRAUMATOLOGY

COLOUR ATLAS OF FORENSIC TRAUMATOLOGY

Version 2

Choking

Prof. Dinesh Fernando
MBBS, MD (Forensic Medicine)
DLM, DMJ (Lond), FCFPSL
Dept. of Forensic Medicine

Dr. Nayani Wijesooriya
MBBS
Dept. of Forensic Medicine

Faculty of Medicine,
University of Peradeniya,
Sri Lanka

Copyright reserved by the authors. However, this book can be freely downloaded or reproduced for non-commercial purposes, since it is meant to be used by medical students and post graduate students in forensic medicine and pathology. However, if any images or part of the book is used for educational purposes, due credit should be attributed to the authors.

In case of any questions, comments, suggestions or errors, please mail the authors on dinesh.fernando@med.pdn.ac.lk / dineshmgfdo@yahoo.com, nayaniwijesooriya@gmail.com

ISBN: 978-624-96229-0-6

Uploaded on 04/10/2024

FOREWORD

The greatest pleasure I experience as a teacher, is to see my students excel in their chosen careers and perform even better than myself. The series of e-booklets prepared to better equip medical officers to handle common conditions likely to be encountered in their day to day forensic practice by Professor Dinesh Fernando, is a good example of one of my students doing better than me!

Dinesh is the son of Emeritus Professor of Community Medicine, Former Head, Department of Community Medicine, Former Dean, Faculty of Medicine and Vice Chancellor of the University of Peradeniya, Malcolm Fernando, who was an illustrious medical academic. Following his father's footsteps, he joined the University of Peradeniya in 2003.

Dinesh was one of my post graduate trainees at the Department of Forensic Medicine and Toxicology, Faculty of Medicine, Colombo, and obtained the doctorate in Forensic Medicine in 2003. He underwent post-doctoral training at the Victorian Institute of Forensic Medicine, Melbourne, Australia, with my colleague and contemporary at Guy's Hospital Medical School, University of London, Professor Stephen Cordner. During this period, he served as the honorary forensic pathologist of the Disaster Victim Identification team in Phuket, Thailand following the tsunami, and was awarded an operations medal by the Australian Federal Police.

He has edited, and contributed chapters to, 'Lecture Notes in Forensic Medicine' authored by the former Chief Judicial Medical Officer, Colombo, Dr. L.B.L. de Alwis and contributed to 'Notes on Forensic Medicine and Medical Law' by Dr. Hemamal Jayawardena. He is the editor of the Sri Lanka Journal of Forensic Medicine, Science and Law. Continuing his writing capabilities, he has compiled an important and unique set of e-booklets which will be a great asset to undergraduate and post-graduate students of Forensic Medicine, and also to our colleagues. Its succinct descriptions of complicated medico-legal issues and clear and educational photographs are excellent. It makes it easy for the students to assimilate the theoretical knowledge of each topic as they have been augmented with histories, examination findings, macroscopic and microscopic photographs of actual cases. In some areas, photographs from multiple cases have been included, so that the students can better appreciate the subtle differences that would be encountered in their practice.

I sincerely thank my ever so grateful student Dinesh, for giving me this great honour and privilege to write the foreword.

Professor Ravindra Fernando

*MBBS, MD, FCCP, FCGP, DMJ (London), FRCP (London)
FRCP (Glasgow), FRCP (Edinburgh), FRCPath. (UK)*

*Senior Professor of Forensic Medicine, General Sir John Kotelawala Defence University, Ratmalana.
Emeritus Professor of Forensic Medicine and Toxicology, Faculty of Medicine, University of Colombo*

About the authors.....

Dr. Dinesh Fernando is a merit Professor in Forensic Medicine at the Faculty of Medicine, University of Peradeniya and honorary Judicial Medical Officer, Teaching Hospital Peradeniya. He obtained his MBBS in 1994 with Second class honours from the North Colombo Medical College, Sri Lanka, and was board certified as a specialist in Forensic Medicine in 2004. He obtained the postgraduate Diploma in Medical Jurisprudence in Pathology from London in 2005, and possesses a certificate of eligibility for specialist registration by the General Medical Council, UK. He underwent post-doctoral training at the Victorian Institute of Forensic Medicine, Melbourne, Australia. He has also worked at the Wellington hospital, New Zealand, as a locum Forensic Pathologist and as an Honorary Clinical Senior Lecturer at the Wellington School of Medicine and Health Sciences, University of Otago, New Zealand. He was invited to visit and share experiences by the Netherlands Forensic Institute in 2019. He was conferred a Fellowship by the College of Forensic Pathologists of Sri Lanka in 2021.

Dr. Nayani Wijesooriya is a Temporary Lecturer at the Department of Forensic Medicine, Faculty of Medicine, University of Peradeniya. She obtained her MBBS in 2024 with Second class honours from the Faculty of Medicine, University of Peradeniya.

PREFACE

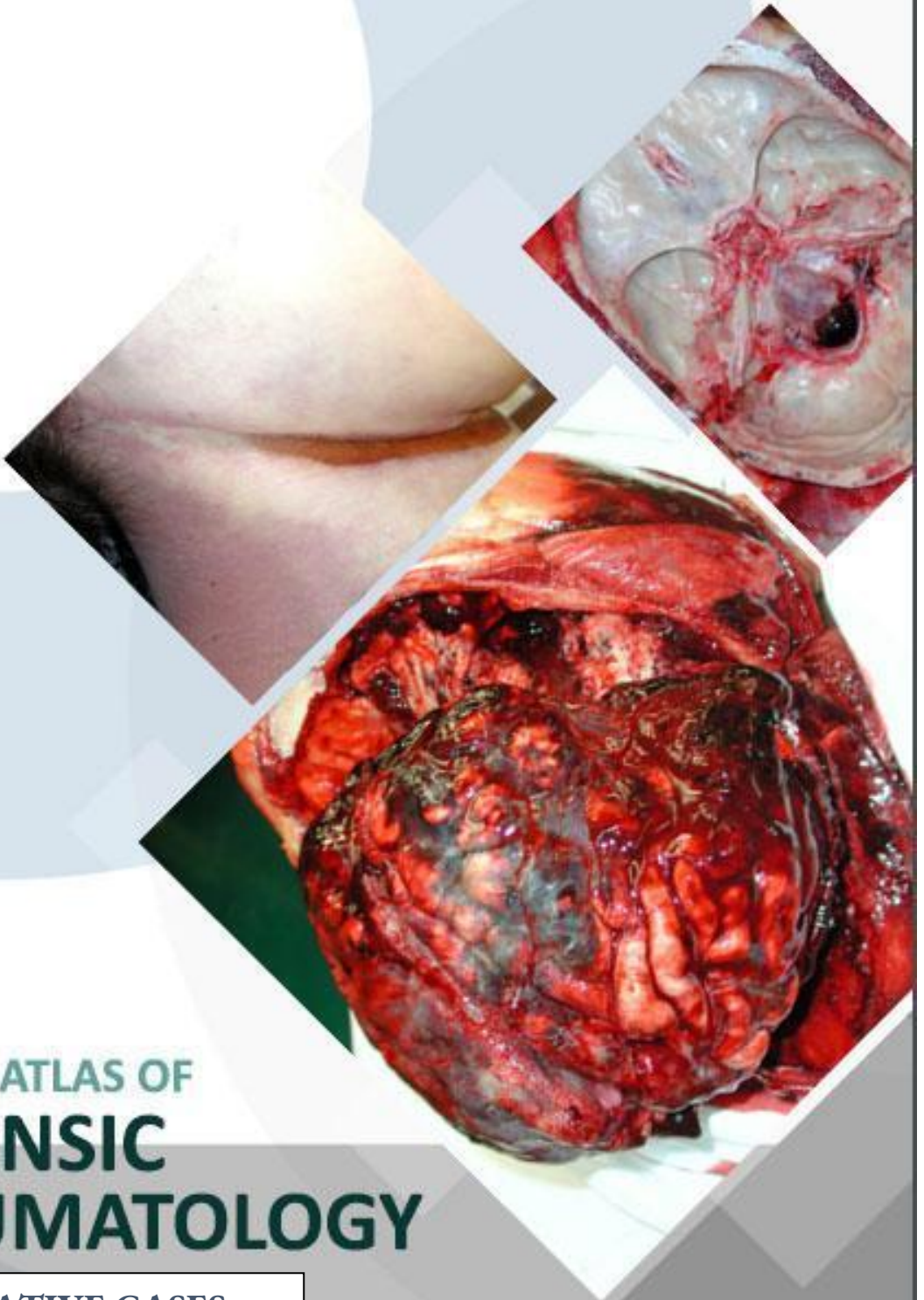Forensic Medicine in Sri Lanka encompasses, both, examination of patients for medico-legal purposes and conducting autopsies in all unnatural deaths, in addition to those that the cause of death is not known. In the eyes of the justice system in Sri Lanka, all MBBS qualified medical officers are deemed to be competent to conduct, report and give evidence on medico-legal examinations of patients and autopsies conducted by them, as an expert witness. However, during their undergraduate training, they may not get the opportunity to assist, nor observe, a sufficient variety of representative of cases that may be encountered in the future.

Therefore, a series of e-booklets has been prepared to better equip medical officers to handle common conditions that are likely to be encountered in day to day forensic practice. The case histories, macro and micro images are from cases conducted by Prof. Dinesh Fernando. Ms. Chaya Wickramarathne did a yeomen service in the initial designing of lay out and formatting the booklet. The compilation of the case and photographs for publication was initiated by Dr. Deshani Herath, continued by Dr. Shashika Weerasinghe, finalized by Dr. Sarangi Amarakoon and updated by Dr. Nayani Wijesooriya.

I gratefully acknowledge Dr. H.D.S.M.Bandara for the history and images of case 03, and Dr. U. Mayorathan for the history and images of cases 05 and 06.

The content herein may be used for academic purposes with due credit given.

Any clarifications, suggestions, comments or corrections are welcome.



COLOUR ATLAS OF
**FORENSIC
TRAUMATOLOGY**

ILLUSTRATIVE CASES

Choking



Choking

Choking is a form of asphyxia caused by an obstruction within the air passages, which can occur under natural, homicidal and accidental circumstances. This obstruction usually occurs between the pharynx and the bifurcation of the trachea.

A natural death can be caused by choking in episodes of acute fulminating epiglottitis, in which there is inflamed epiglottis and surrounding soft tissue causing airway obstruction. This can also occur in steam inhalation. Homicidal deaths by choking are relatively uncommon. Infants may be occasionally murdered by stuffing toilet paper into the mouth. In adults, individuals sometimes die during a robbery or burglary when a cloth or sock is rammed into the mouth to silence the individual. This is often done in conjunction with gagging. Most choking deaths occur accidentally, where unintentional inhalation of food or other objects leading to airway obstruction.

Causes of choking include obstruction by a food bolus, foreign body inhalation (e.g. small toys, dentures), haemorrhages (e.g. Blood clots, and frank haemorrhages following dental or ear, nose and throat operations such as tonsillectomy) and acute obstructive lesions of glottis and larynx (e.g. oedema due to acute hypersensitivity reactions including insect stings, irritant vapours, inhalation of hot gas and acute infective conditions). The most dangerous acute infection is diphtheria or *Haemophilus influenzae* epiglottitis in children, which is a medical emergency sometimes requiring an immediate tracheostomy to relieve the airway obstruction. In children, choking occurs when the child aspirates small objects, whereas, in adults, it mostly involves food, especially when the person is intoxicated. The piece of food will wedge in the laryngopharynx and larynx, completely obstructing the airway. Such deaths have acquired the name 'cafe coronary'. In that scenario sudden collapse of healthy subjects occurs while they are having meals, in the absence of any signs of asphyxia, respiratory distress or neurological symptoms. If the respiratory passage below the larynx is completely obstructed by food, the death can be attributed to choking. There are no specific post-mortem findings indicating choking, except for the obstructed airway. Death occurs due to hypoxia caused by airway obstruction. If the victim had struggled for a significant period, the signs of asphyxia like congestion, cyanosis and petechiae may be present. But most deaths due to choking occur suddenly before the development of these signs. This sudden death could be mediated by neurogenic cardiac arrest.

When food obstructs the airways, it can reach the airways from the mouth in the act of swallowing or from the stomach due to regurgitation. The first instance occurs commonly in elderly and mentally disturbed patients, even though it can occur in any age group. The post-mortem investigations may show the obstructing agent in the airway with a reaction at the point of obstruction. The aspiration of gastric content can be suspected by a reliable history or with histological findings of an advanced vital reaction with infection, necrosis and an inflammatory reaction. But the presence of small amounts of gastric content in the airway is not diagnostic of choking, since many patients aspirate food agonally, independent of the cause of death.

Case 01:**History**

A 52-year-old male, who had no teeth and had a tendency to swallow his food without chewing, had choked on food. He had frequently choked on food in the past. Heimlich manoeuvre was performed unsuccessfully and attempts made to remove the obstacle were unsuccessful. The patients' GCS was 3 at the time of admission and a large piece of food material was removed from the airway. Resuscitation efforts produced a rhythm which turned into asystole and further CPR was not successful.

External Examination

No food material or injuries were noted in the oral cavity. Both upper and lower jaws were edentulous.

Internal Examination

Respiratory System: Adhesions were present between the right lung and the chest wall. There were no collections of air, fluid or blood. The larynx, trachea and main stem bronchi were unremarkable externally and contained food-like material within the lumen up to the tertiary divisions of the bronchi. The mucosal surface was intensely congested. The hyoid bone and the thyroid cartilage were intact. No haemorrhagic areas were noted among the neck organs.

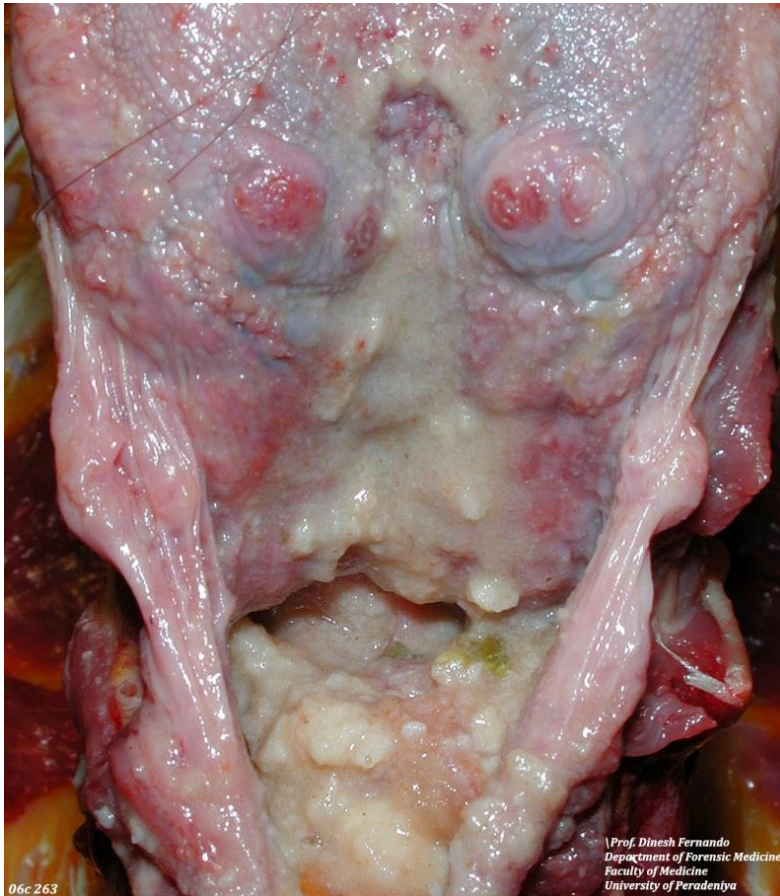

Figure 1: Food-like material in the trachea.

Microscopic Examination

Respiratory system: Vessels were congested and there were areas of severe intra-alveolar haemorrhage. Bronchi and bronchioles were obstructed by abundant vegetable material.

To demonstrate the above microscopic findings, the following histological images are taken from another case.

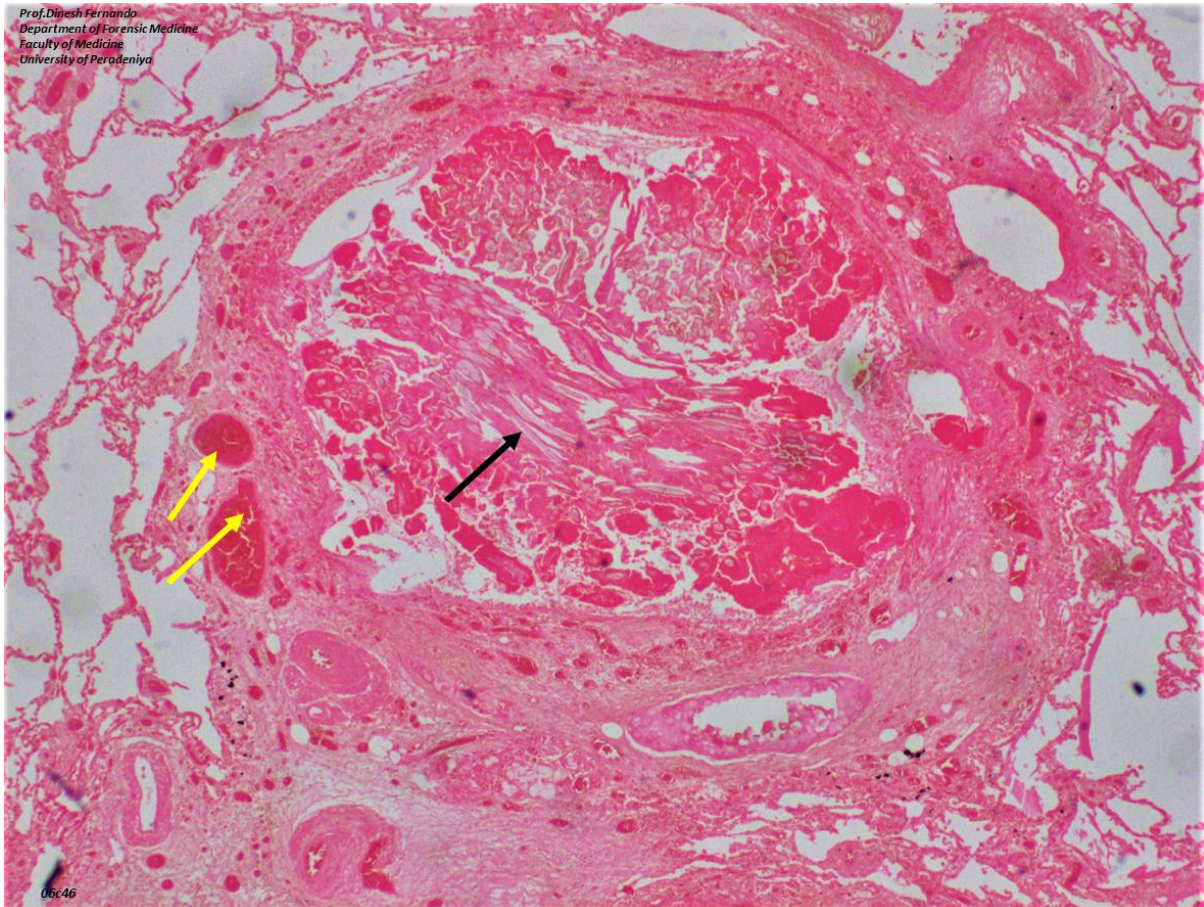


Figure 2(a): H&E low power; congested blood vessels (yellow arrows); obstructed bronchus with vegetable material (black arrow).

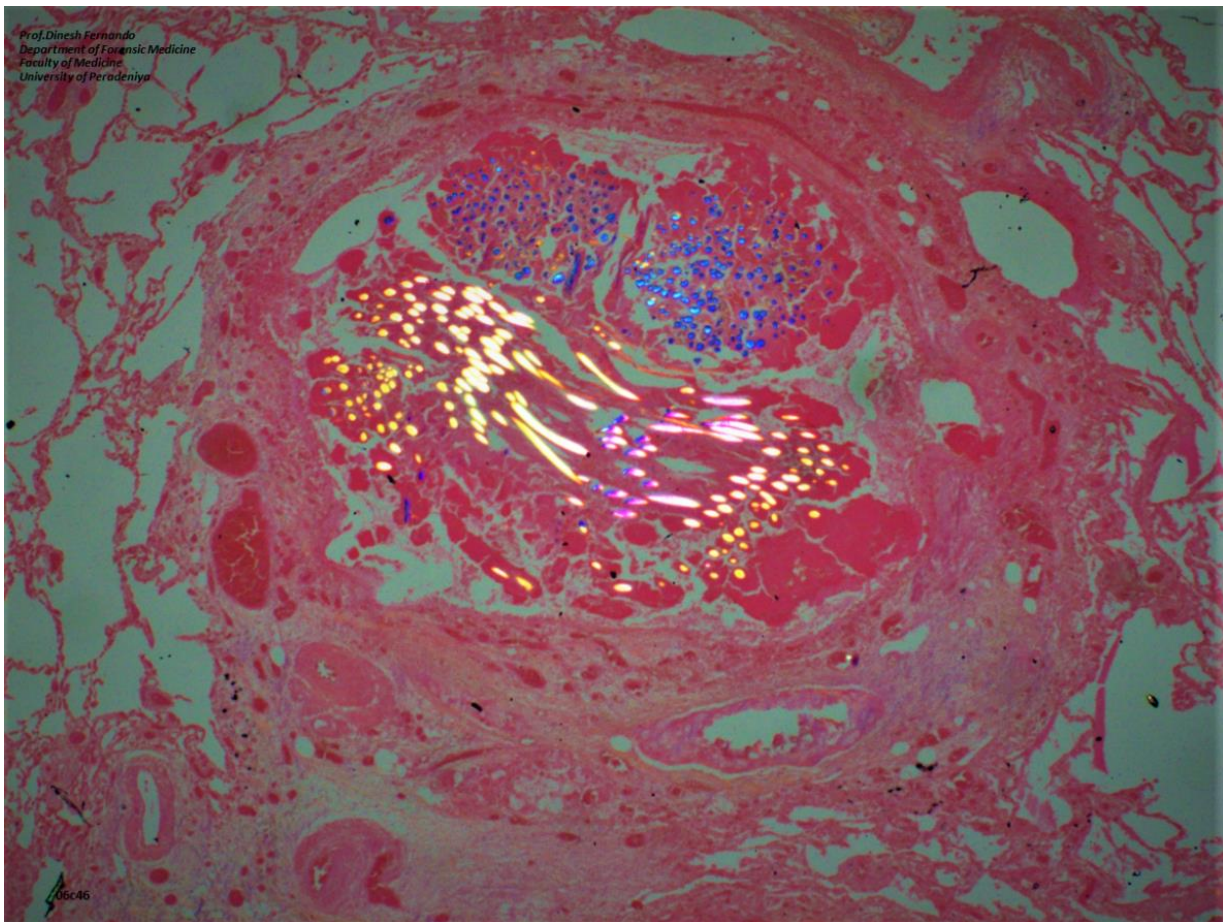


Figure 2(b): Vegetable material is highlighted by polarization.

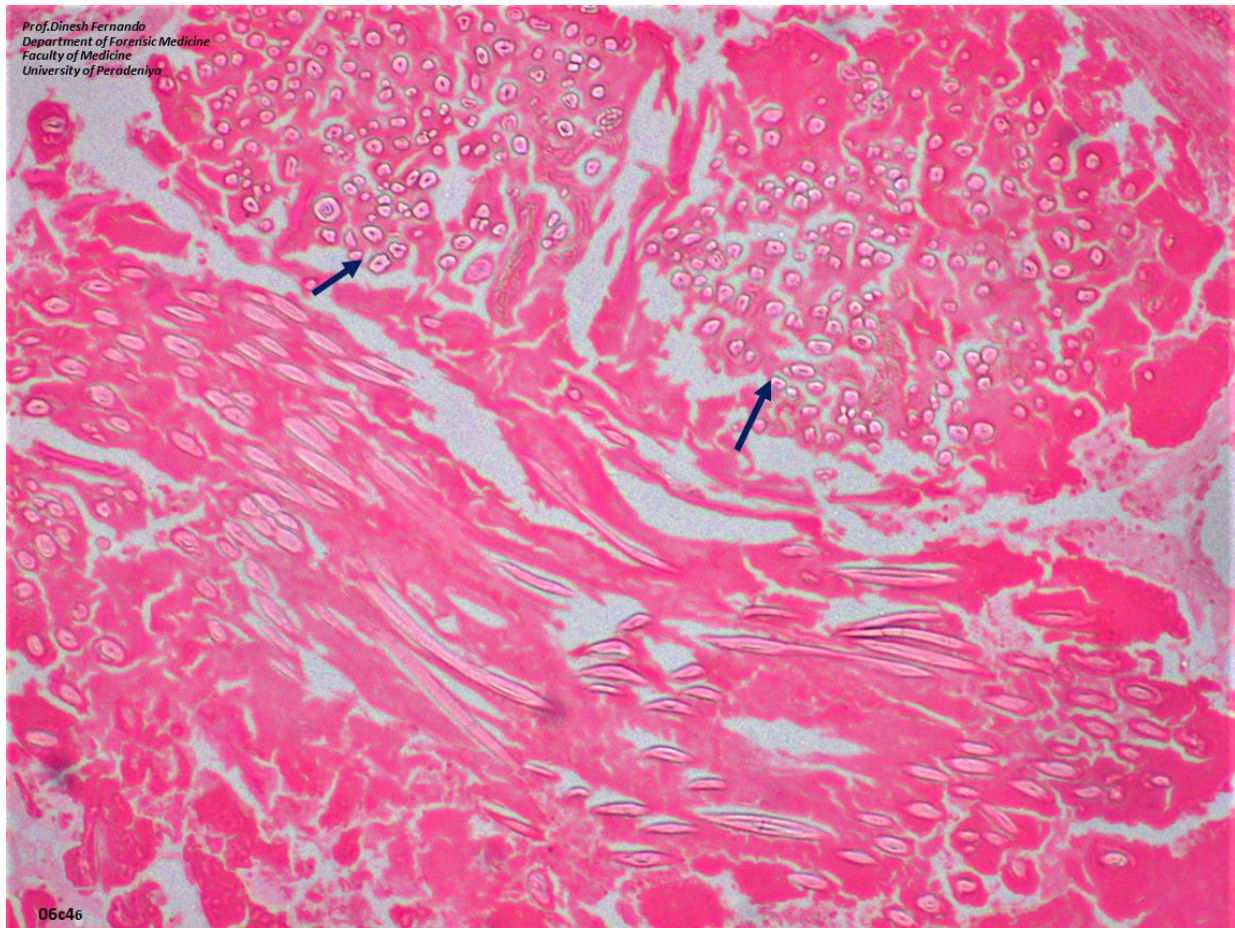


Figure 2(c): H&E high power; vegetable material within the bronchus.

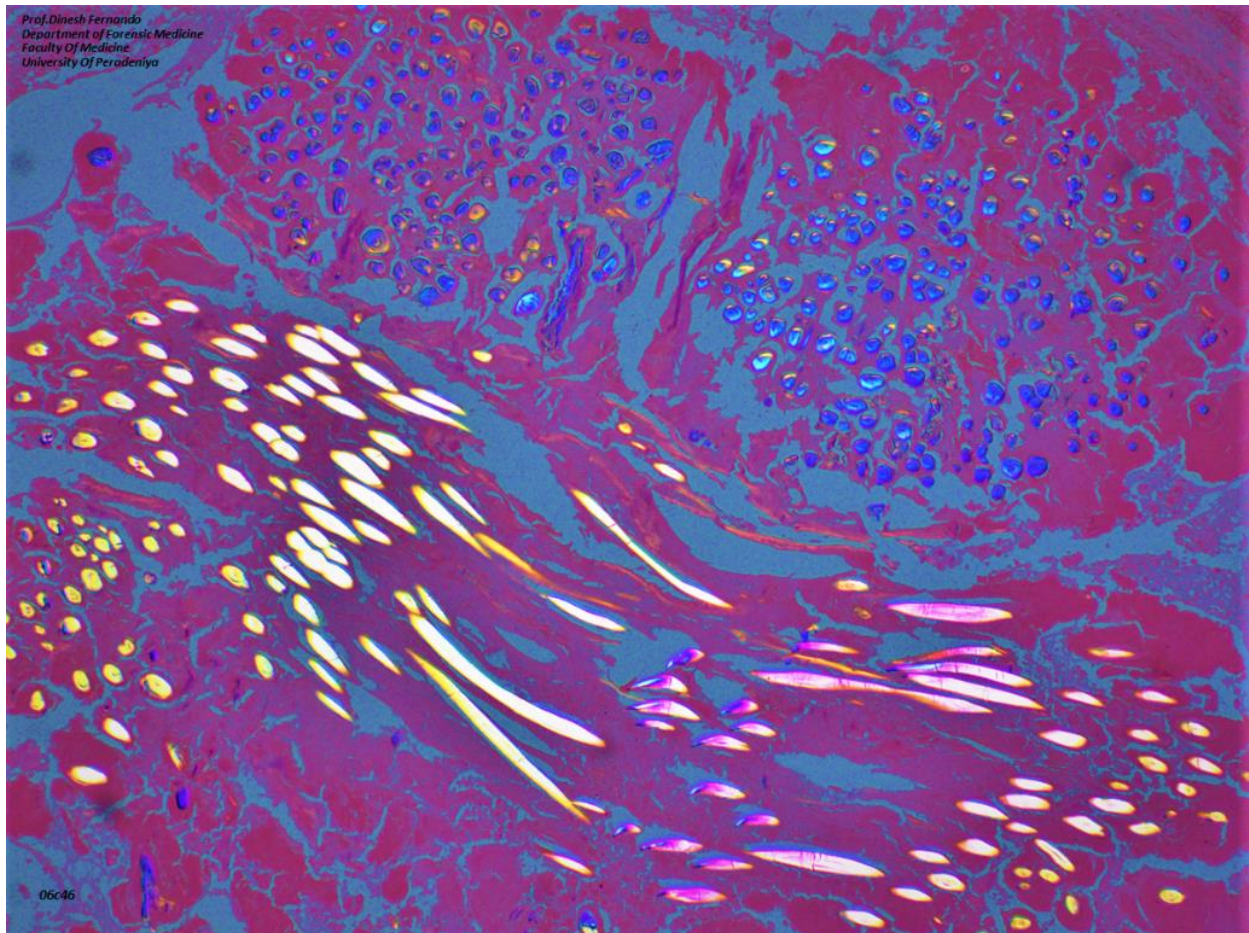


Figure 2(d): H&E high power; polarized.

Cause of death

Consistent with the history of choking.

Case 02:**History**

A 76-year-old female, with a recent history of two mild strokes, complained of difficulty in swallowing immediately after eating food. She had a history of swallowing difficulty following the stroke. She complained of difficulty in breathing and a short time later collapsed unconscious. She was declared dead at the hospital.

External Examination

The sclerae were not icteric and the conjunctivae were free of petechial haemorrhages. Food material was present in the oral cavity which was free of injuries. Natural teeth were present in the upper and lower jaw.

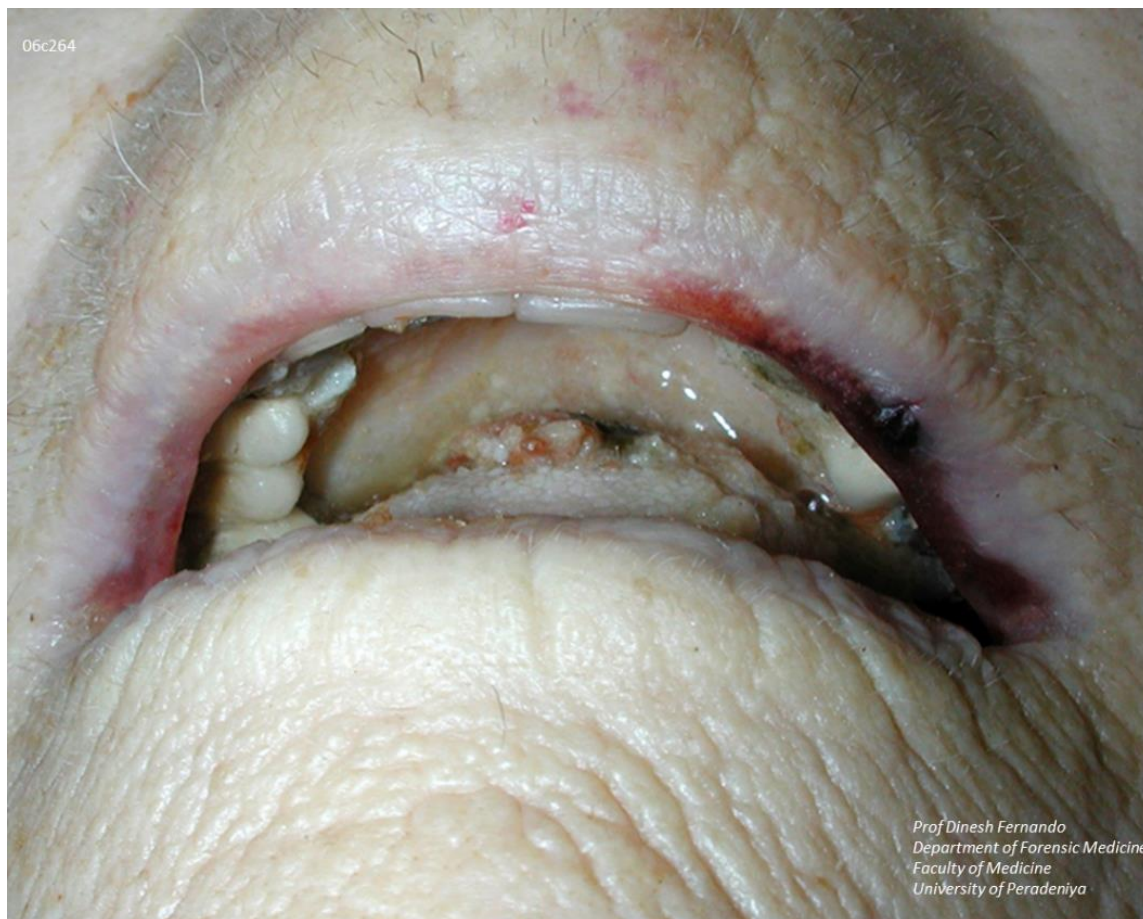

Figure 3: Food-like material in the oral cavity.

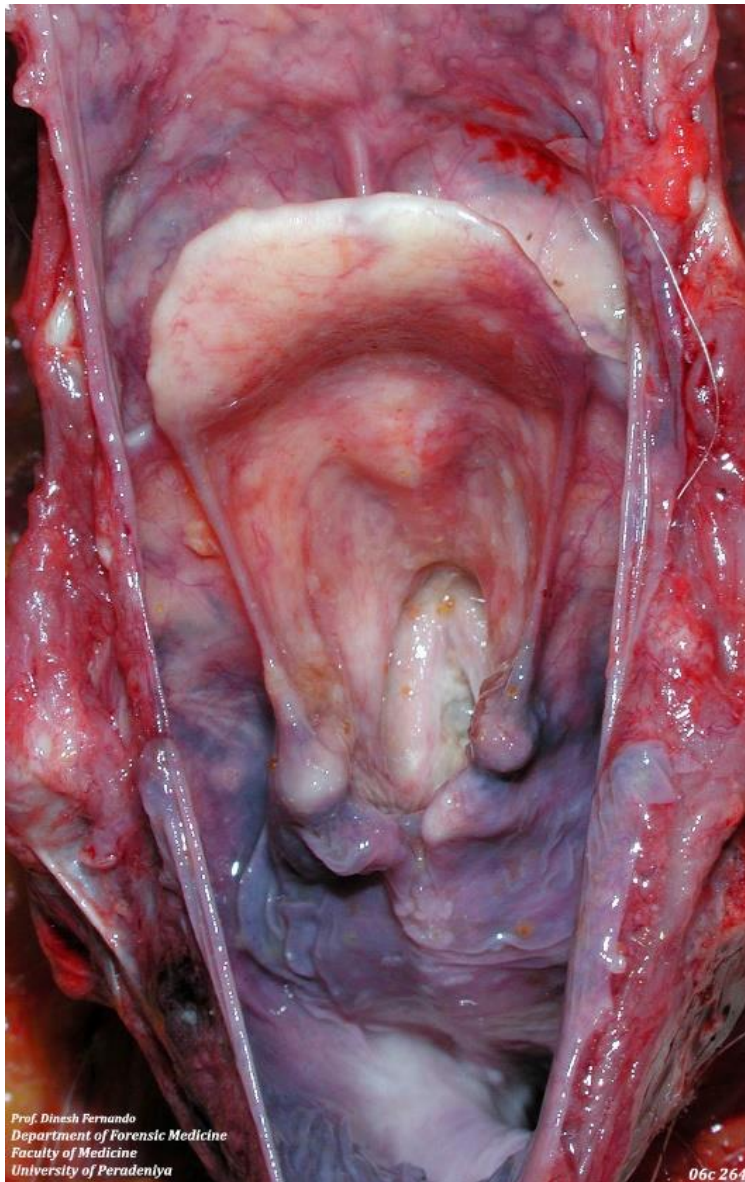

Figure 4: Food like material in the larynx (glottis) with congested mucosa.

Internal Examination

Respiratory System: Both lungs were adherent to the chest cavities. There were no collections of air, fluid or blood. The larynx, trachea and main stem bronchi were unremarkable externally and contained food-like material within the lumina. Food-like material was present up to the tertiary divisions of the bronchi. The mucosal surfaces were markedly congested. The hyoid bone and the thyroid cartilage were intact.

06c 264

*Prof. Dinesh Fernando
Department of Forensic Medicine
Faculty of Medicine
University of Peradeniya*

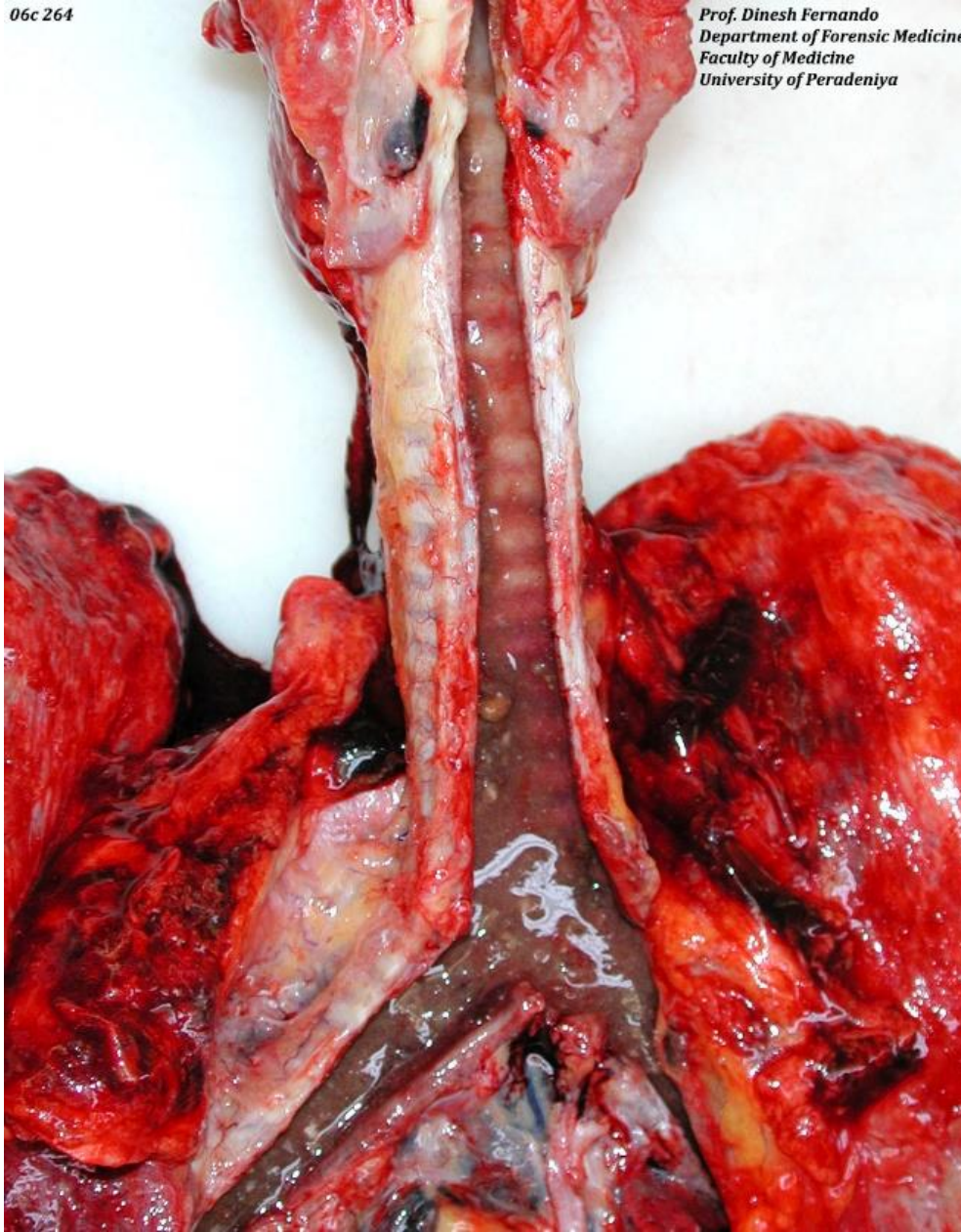


Figure 5: food like material in the trachea and main bronchi

Cause of death

Consistent with the history of choking.

**Case 03:****History**

A 57-year-old man was fishing in an anicut in a rural area in Sri Lanka. The fish that was caught, had been placed between his teeth while he was baiting the hook again. The struggling fish, slid down his throat, resulting in the death of both of them. The deceased was brought to hospital, by a passer-by who found the victim gasping and struggling for breath. Death was declared on admission.

External examination

The fishtail was seen through the mouth opening. No petechial haemorrhages in the eyes. Natural teeth were present in both upper and lower jaws. Dentures were present.

Blood and secretions were present around the orifice of the mouth and in the oral cavity.

Internal Examination

Parts of the oesophagus and the larynx were obstructed by the fish. The laryngeal skeleton was free of injuries. The trachea and bronchi were patent and were free of injuries.

Cause of death

Obstruction of the pharynx by a live fish.

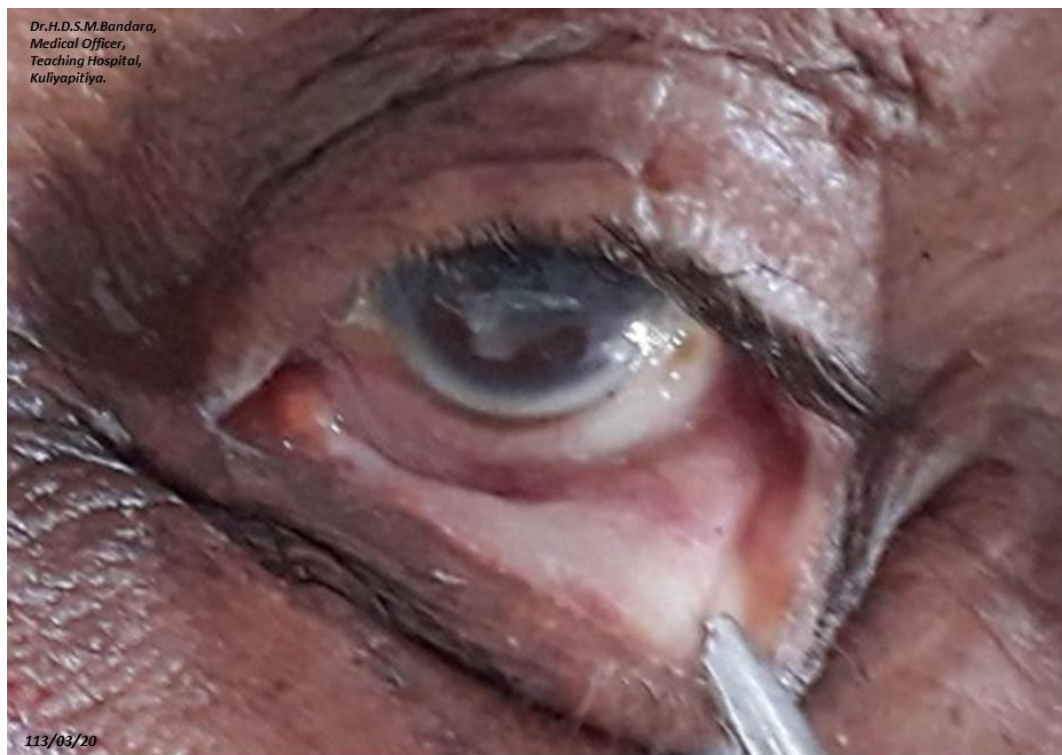

Figure 6: pale conjunctiva without petechial haemorrhages.



Dr. H.D.S.M. Bandara,
Medical Officer,
Teaching Hospital,
Kuliyapitiya.

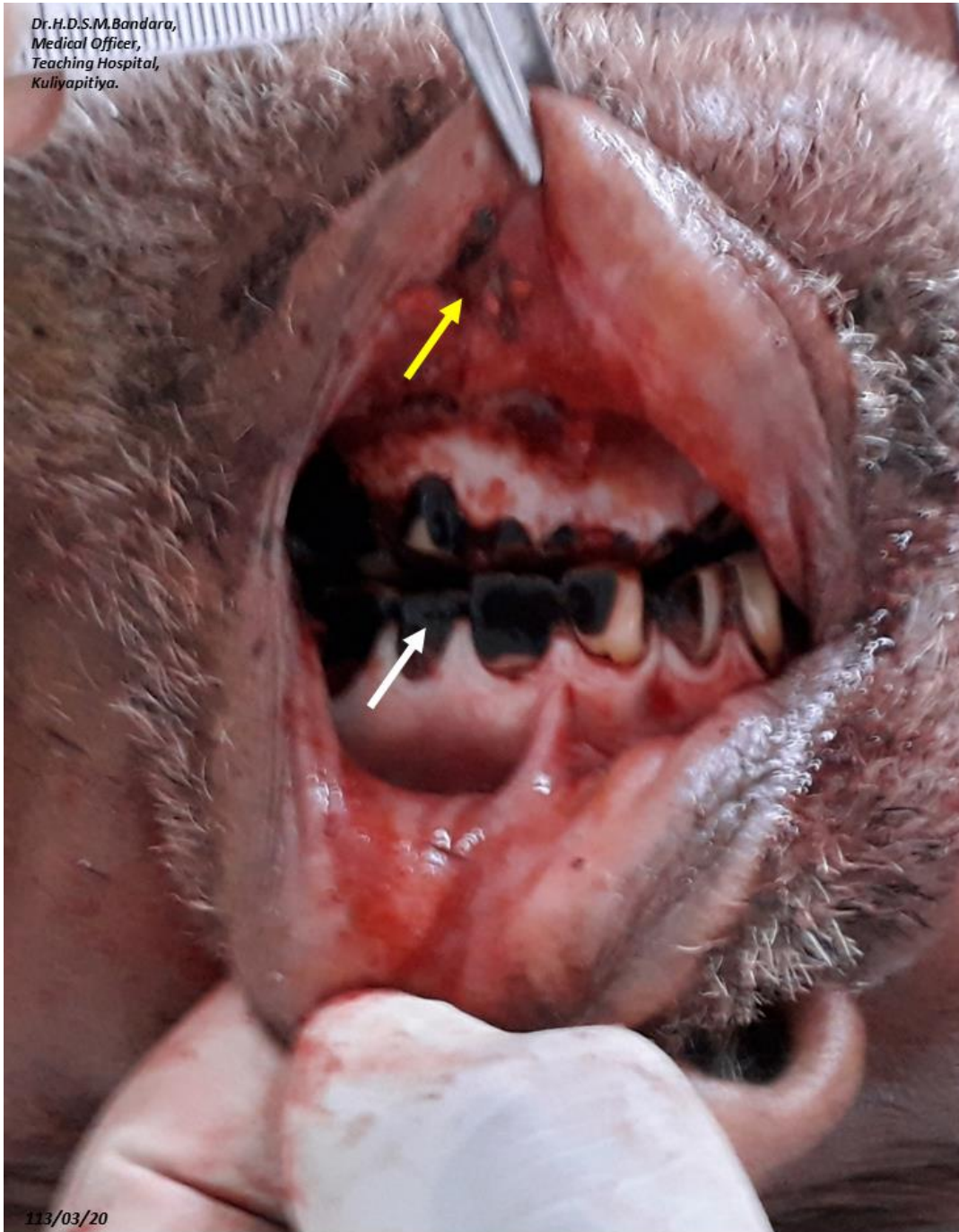

Figure 7: oral cavity with stained teeth (white arrow) and associated periodontal disease along with lacerated lower lips (yellow arrow).

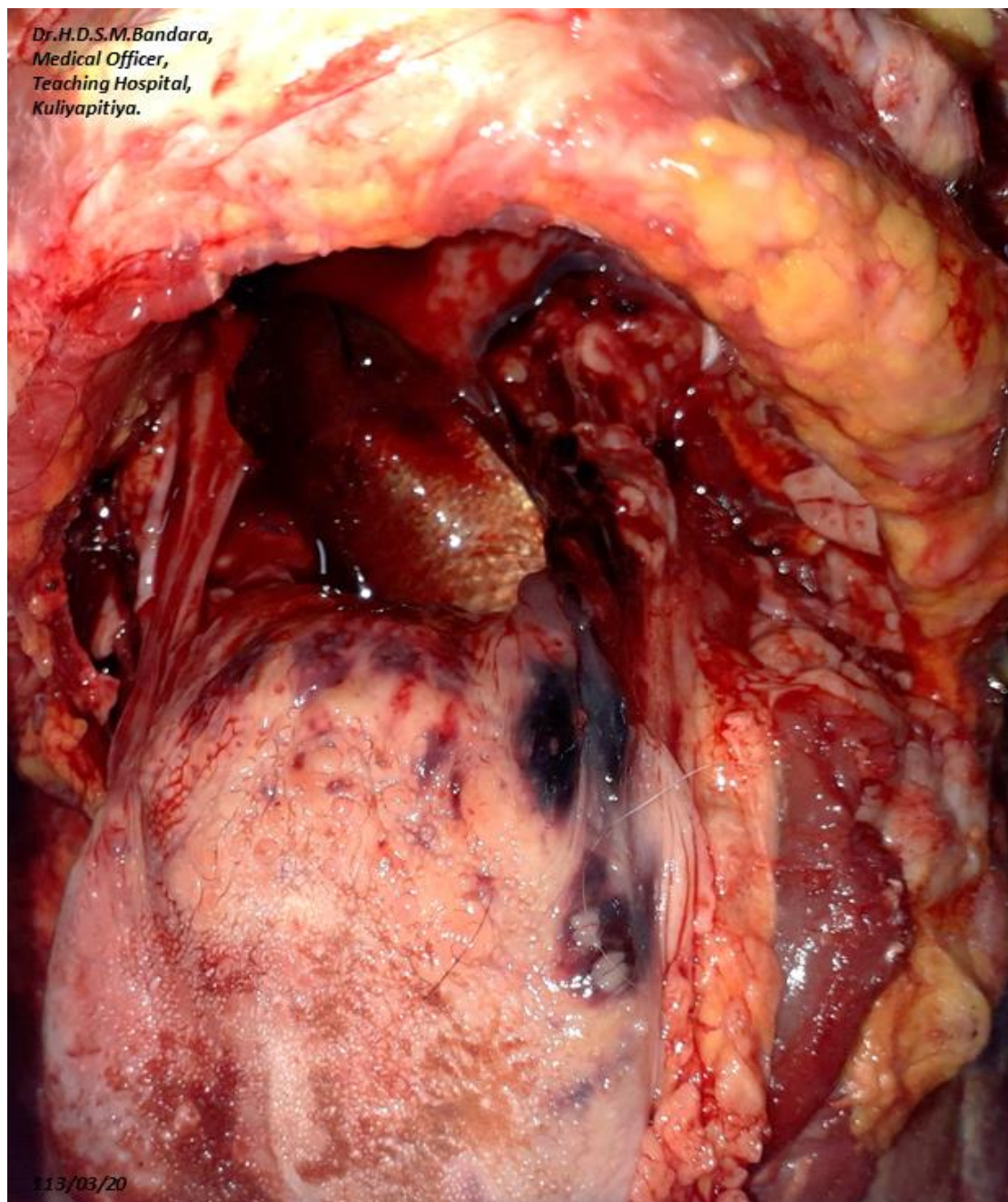


Figure 8: Note the haemorrhages on the base of the tongue and the fish tail obstructing the pharynx.

Case 04:**History**

A previously healthy 4-year-old female child presented with a 2-day history of fever and cold. There was no cough. The child's mother is abroad, and she was being cared for by her grandmother and father. The grandmother administered a paracetamol (PCM) tablet to the child due to high fever. Shortly after ingestion, the child's eyes rolled up, and she collapsed. She was taken to Mahiyanganaya DH within 10-12 minutes and later transferred to THP Peradeniya. She was managed as a choking episode following the ingestion of the PCM tablet in the ICU. There is no history of food or drug allergies.

Internal Examination

The trachea and vocal cords were inflamed. The right lung weighed 200 g and the left lung weighed 180 g (normal lung weight for a 4-year-old child: right lung 90 g, left lung 85 g). The lungs showed bilateral subpleural haemorrhages and bilateral ARDS. The brain was oedematous and weighed 1110 g (normal brain weight for a 4-year-old child: 1190 g).

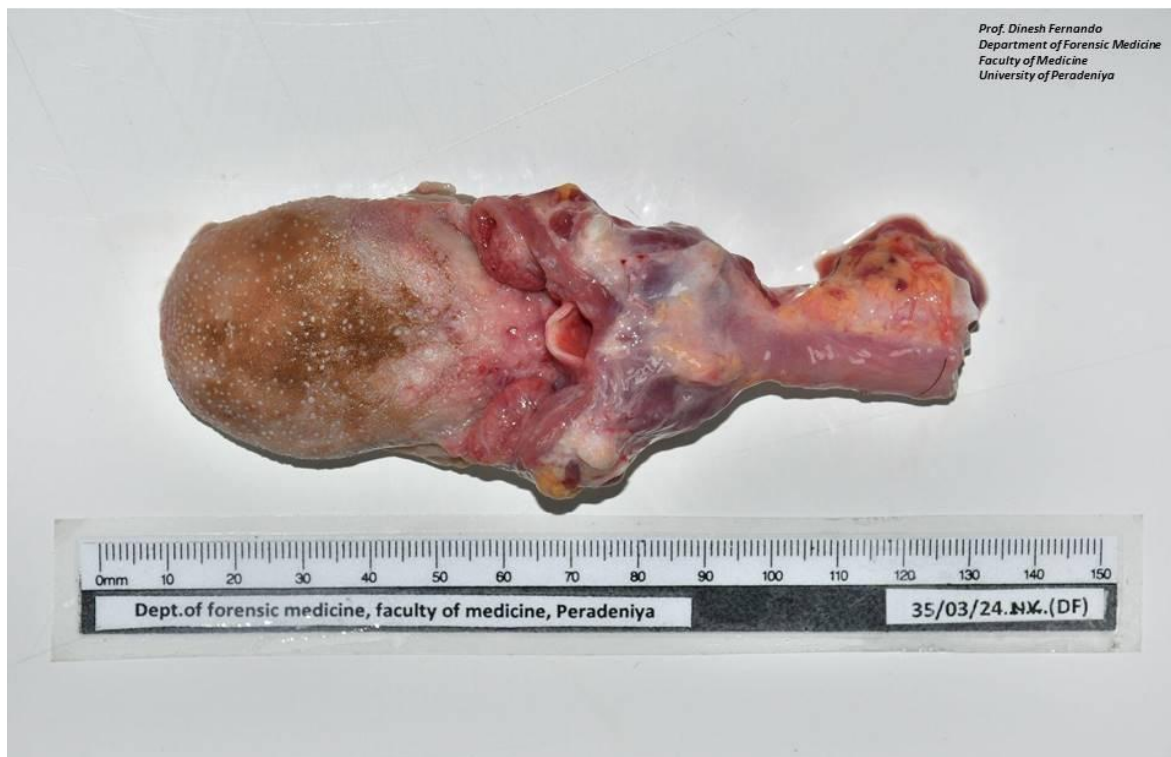

Figure 10: Appearance at the post-mortem examination.



Figure 11: Mounted museum specimen with paracetamol tablet in situ in the larynx (re-creation).

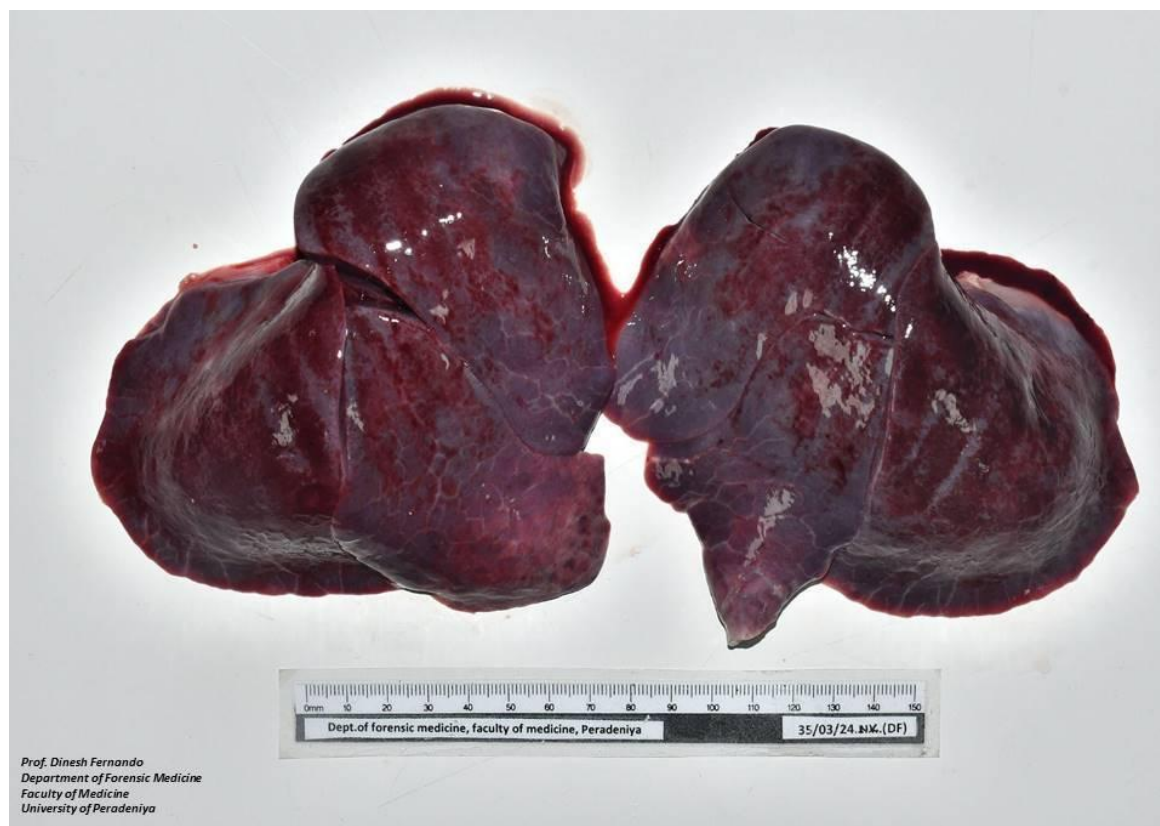

Figure 12: Bilateral subpleural haemorrhages.

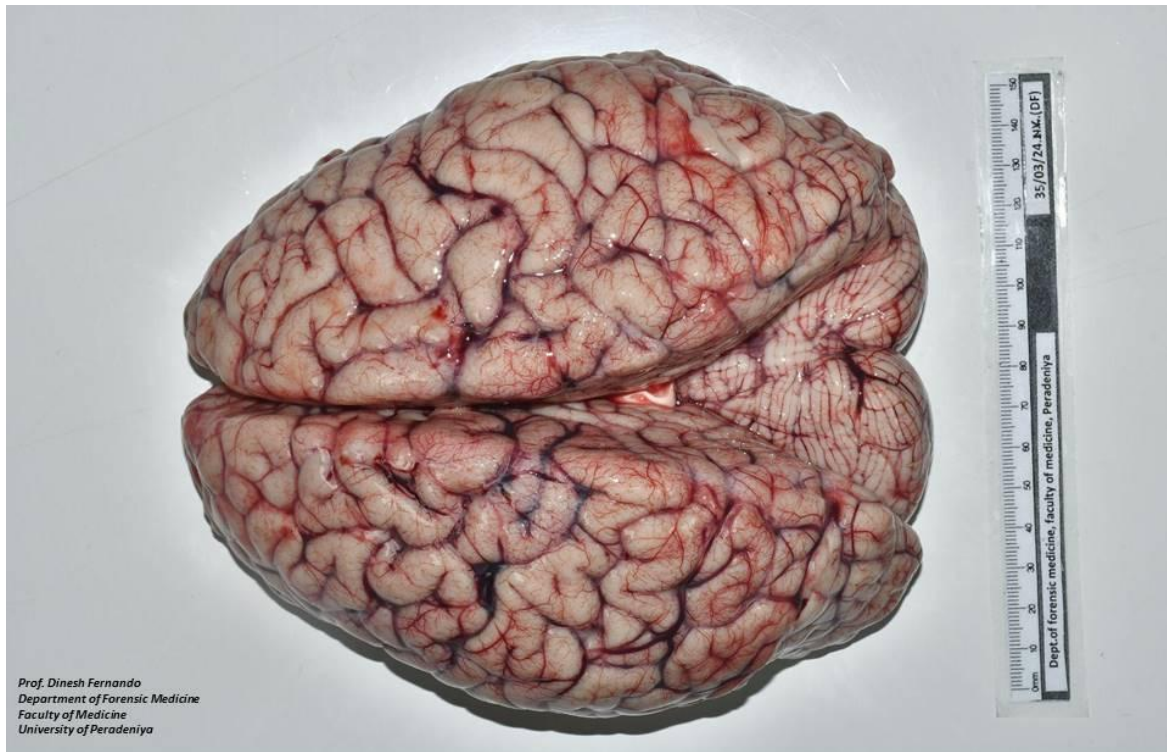


Figure 13: Oedematous brain. Note the obliteration of sulci and flattened gyri.

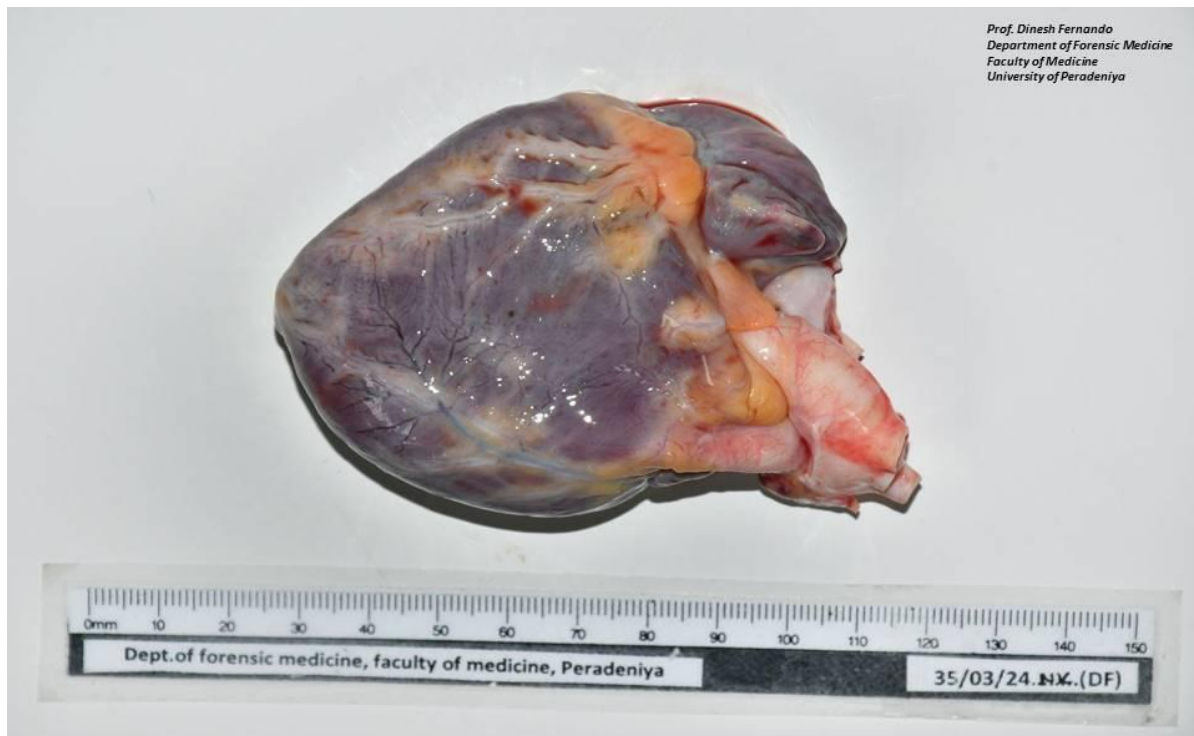

Figure 14: Tardieu spots in the pericardium.

(Images of Tardieu spots are also shown on page 19 of the chapter on Valvular Heart Disease, in volume II of the [Colour Atlas of Forensic Pathology](#) and on page 7 of the chapter on Asphyxia, in volume I of the [Colour Atlas of Forensic Traumatology](#).)

Microscopic examination

The brain showed cerebral oedema, mild liquefactive necrosis, mild cellular necrosis, and a few red neurons. No foreign body aspiration was noted in the lungs.

Cause of death

Hypoxic brain injury compatible with the history of choking due to obstruction of the larynx by a foreign body (paracetamol tablet).

**Case 05:****History**

A previously healthy three-year-old child suddenly developed noisy breathing and restlessness while playing. The child became blue and had held her neck with both hands. Even though she was rushed to the nearby hospital, she was pronounced dead at the outpatient department. The autopsy revealed airway obstruction by a paracetamol tablet lodged in the epiglottic region.

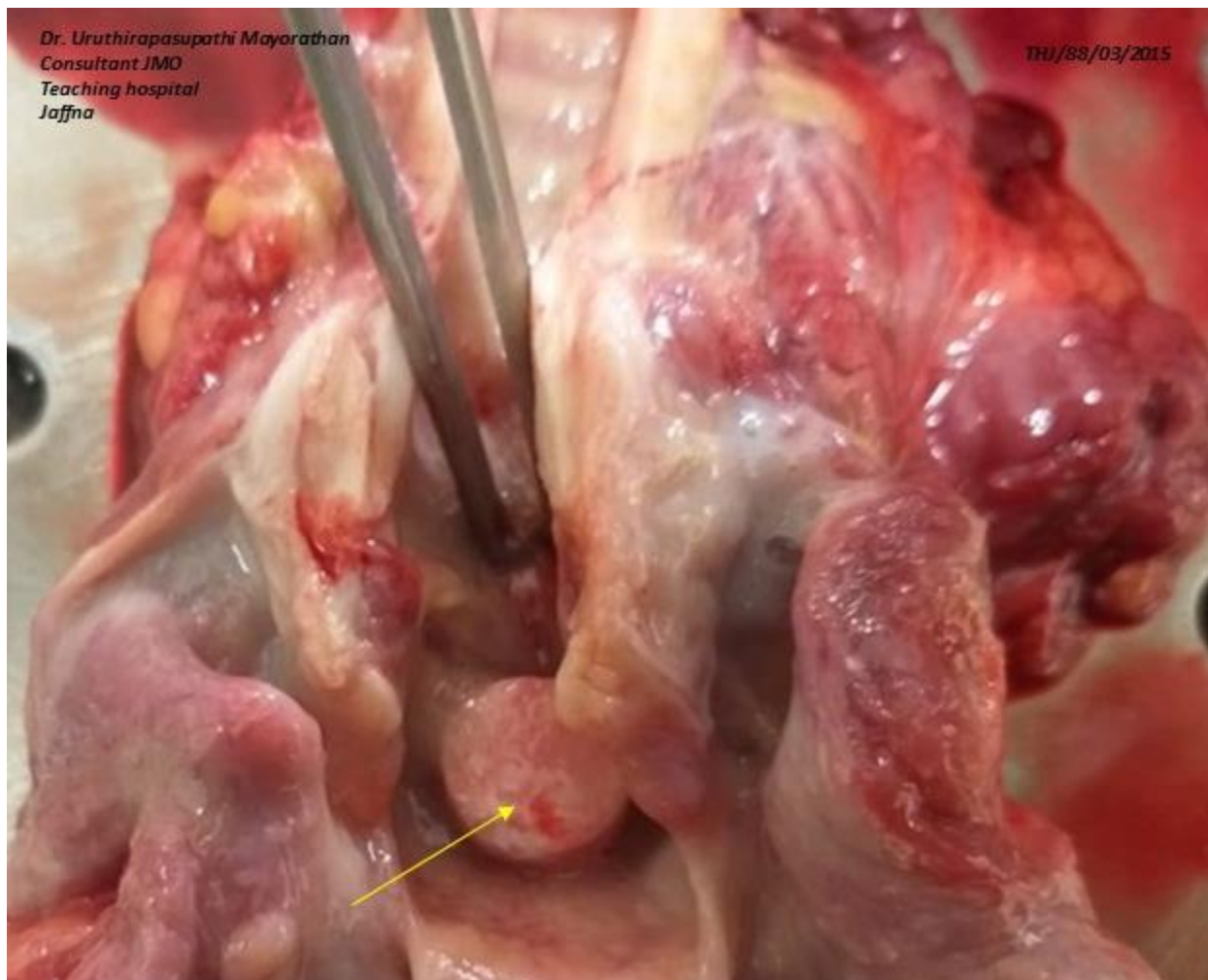

Figure 15: A paracetamol tablet stuck in the epiglottic region.

Case 06:**History**

A previously healthy child aged two and a half years, suddenly collapsed while being fed. She was admitted to the accident and emergency department but could not be revived. The autopsy revealed the presence of two half-peanuts at the bifurcation of the trachea and some food particles in the lower airways.

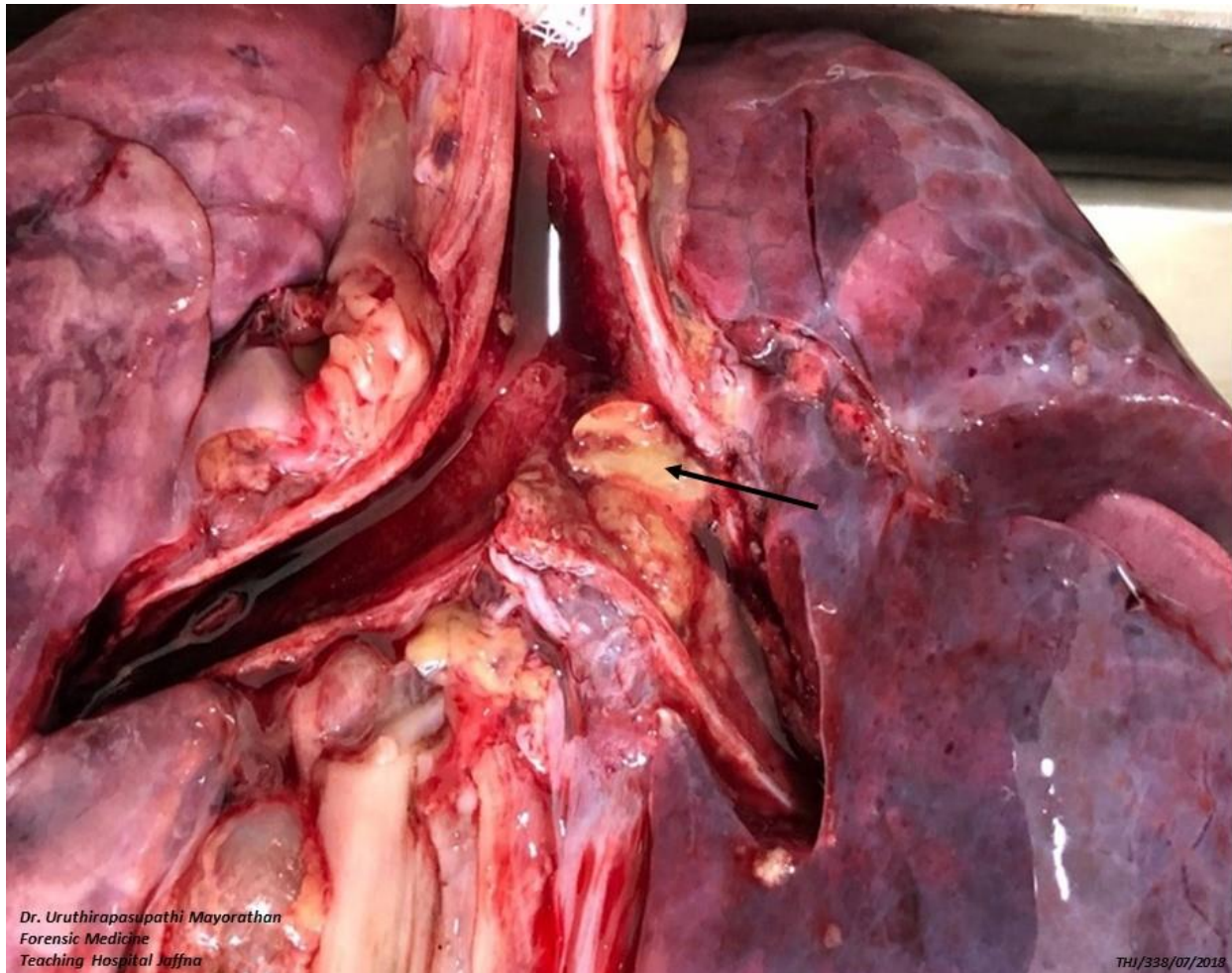


Figure 16: Obstruction by two halves of peanuts at the level of bifurcation.



Bibliography

1. Di Maio DJ, Di Maio VJM. *Forensic Pathology*. 2nd ed. Boca Raton: CRC press; 2001
2. Saukko P, Knight B. *Knight's forensic pathology*. 4th ed. Boca Raton: CRC press; 2015
3. James JP, Jones R, Karch SB, Manlove J. *Simpson's Forensic Medicine*. 13th ed. London: Hodder Arnold; 2011
4. Dolinak D, Matshes EW, Lew EO. *Forensic Pathology Principles and Practice*. 1st ed. London: Elsevier Academic Press; 2005
5. Mayorathan, U., Manikkavasakar, S., & Pranavan, S. (2022). Accidental Choking in Children: An Area To Be Focused on. *Cureus*, 14(2), e22459. <https://doi.org/10.7759/cureus.22459>