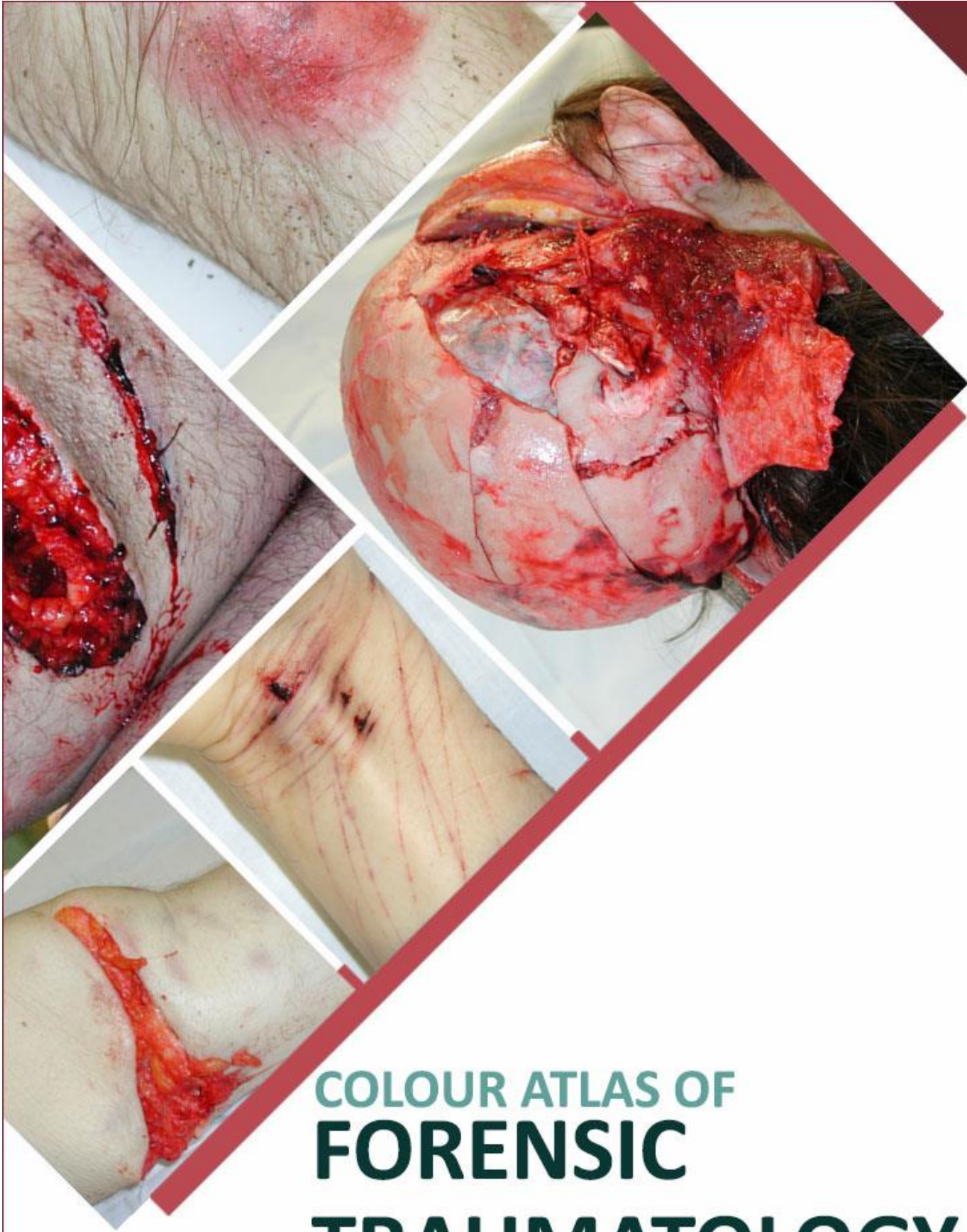



COLOUR ATLAS OF
FORENSIC
TRAUMATOLOGY

COLOUR ATLAS OF FORENSIC TRAUMATOLOGY

Version 1

Asphyxia

Prof. Dinesh Fernando
MBBS, MD (Forensic Medicine)
DLM, DMJ (Lond), FCFPSL
Dept. of Forensic Medicine

Dr. Sarangi Amarakoon
MBBS
Dept. of Forensic Medicine

Faculty of Medicine,
University of Peradeniya,
Sri Lanka

Copyright reserved by the authors. However, this book can be freely downloaded or reproduced for non-commercial purposes, since it is meant to be used by medical students and post graduate students in forensic medicine and pathology. However, if any images or part of the book is used for educational purposes, due credit should be attributed to the authors.

In case of any questions, comments, suggestions or errors, please mail the authors on dinesh.fernando@med.pdn.ac.lk, lakshaniamarakoon2015@gmail.com

ISBN: 978-624-96229-0-6

Uploaded on 05/10/2023

FOREWORD

The greatest pleasure I experience as a teacher, is to see my students excel in their chosen careers and perform even better than myself. The series of e-booklets prepared to better equip medical officers to handle common conditions likely to be encountered in their day to day forensic practice by Professor Dinesh Fernando, is a good example of one of my students doing better than me!

Dinesh is the son of Emeritus Professor of Community Medicine, Former Head, Department of Community Medicine, Former Dean, Faculty of Medicine and Vice Chancellor of the University of Peradeniya, Malcolm Fernando, who was an illustrious medical academic. Following his father's footsteps, he joined the University of Peradeniya in 2003.

Dinesh was one of my post graduate trainees at the Department of Forensic Medicine and Toxicology, Faculty of Medicine, Colombo, and obtained the doctorate in Forensic Medicine in 2003. He underwent post-doctoral training at the Victorian Institute of Forensic Medicine, Melbourne, Australia, with my colleague and contemporary at Guy's Hospital Medical School, University of London, Professor Stephen Cordner. During this period, he served as the honorary forensic pathologist of the Disaster Victim Identification team in Phuket, Thailand following the tsunami, and was awarded an operations medal by the Australian Federal Police.

He has edited, and contributed chapters to, 'Lecture Notes in Forensic Medicine' authored by the former Chief Judicial Medical Officer, Colombo, Dr. L.B.L. de Alwis and contributed to 'Notes on Forensic Medicine and Medical Law' by Dr. Hemamal Jayawardena. He is the editor of the Sri Lanka Journal of Forensic Medicine, Science and Law. Continuing his writing capabilities, he has compiled an important and unique set of e-booklets which will be a great asset to undergraduate and post-graduate students of Forensic Medicine, and also to our colleagues. Its succinct descriptions of complicated medico-legal issues and clear and educational photographs are excellent. It makes it easy for the students to assimilate the theoretical knowledge of each topic as they have been augmented with histories, examination findings, macroscopic and microscopic photographs of actual cases. In some areas, photographs from multiple cases have been included, so that the students can better appreciate the subtle differences that would be encountered in their practice.

I sincerely thank my ever so grateful student Dinesh, for giving me this great honour and privilege to write the foreword.

Professor Ravindra Fernando

*MBBS, MD, FCCP, FCGP, DMJ (London), FRCP (London)
FRCP (Glasgow), FRCP (Edinburgh), FRCPath. (UK)*

*Senior Professor of Forensic Medicine, General Sir John Kotelawala Defence University, Ratmalana.
Emeritus Professor of Forensic Medicine and Toxicology, Faculty of Medicine, University of Colombo*

About the authors.....

Dr. Dinesh Fernando is a merit Professor in Forensic Medicine at the Faculty of Medicine, University of Peradeniya and honorary Judicial Medical Officer, Teaching Hospital Peradeniya. He obtained his MBBS in 1994 with Second class honours from the North Colombo Medical College, Sri Lanka, and was board certified as a specialist in Forensic Medicine in 2004. He obtained the postgraduate Diploma in Medical Jurisprudence in Pathology from London in 2005, and possesses a certificate of eligibility for specialist registration by the General Medical Council, UK. He underwent post-doctoral training at the Victorian Institute of Forensic Medicine, Melbourne, Australia. He has also worked at the Wellington hospital, New Zealand, as a locum Forensic Pathologist and as an Honorary Clinical Senior Lecturer at the Wellington School of Medicine and Health Sciences, University of Otago, New Zealand. He was invited to visit and share experiences by the Netherlands Forensic Institute in 2019. He was conferred a Fellowship by the College of Forensic Pathologists of Sri Lanka in 2021.

Dr. Sarangi Amarakoon is a Temporary Research Assistant at the Department of Forensic Medicine. She obtained her MBBS in 2023 with Second class honours from the Faculty of Medicine, University of Peradeniya.

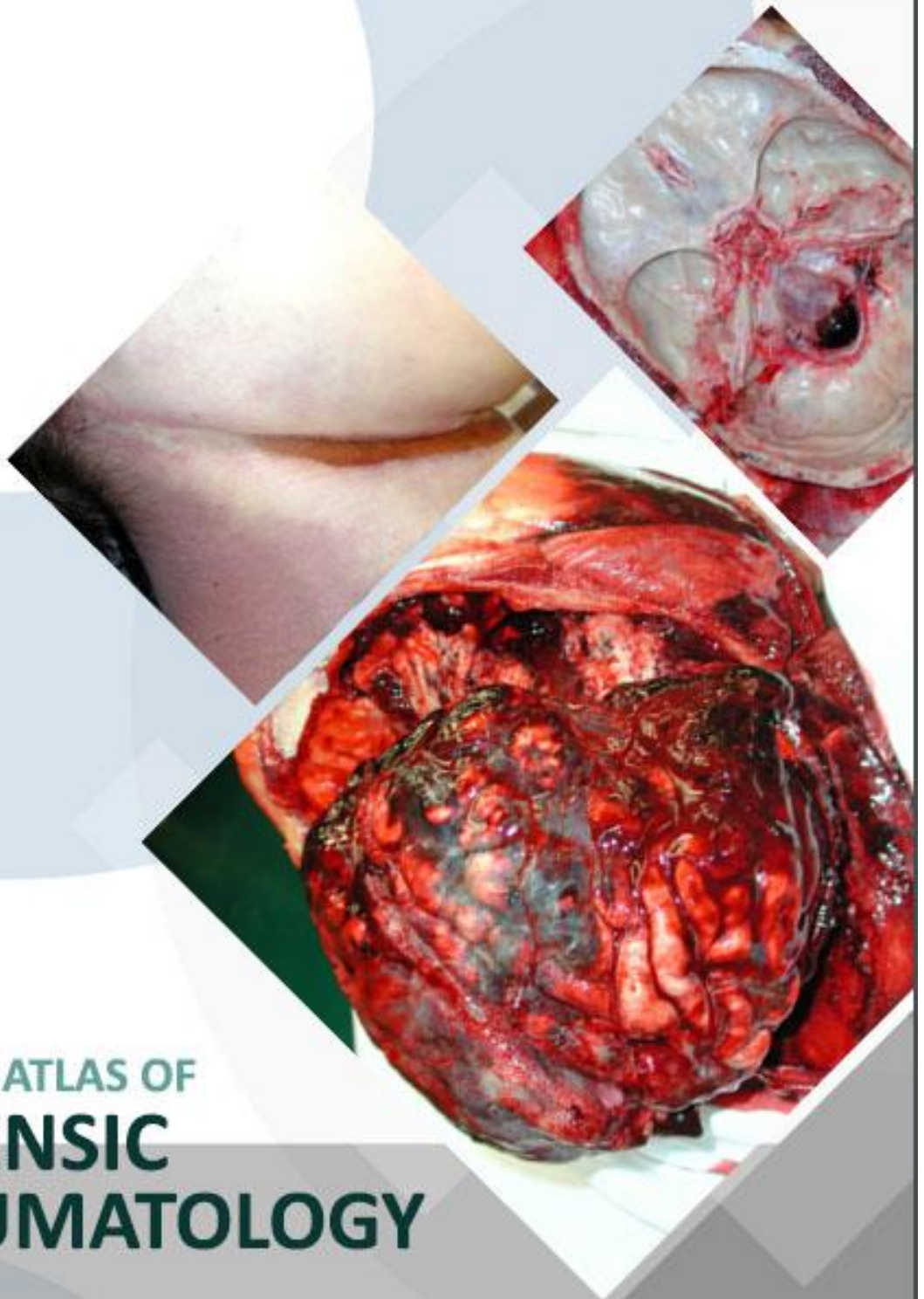PREFACE

Forensic Medicine in Sri Lanka encompasses, both, examination of patients for medico-legal purposes and conducting autopsies in all unnatural deaths, in addition to those that the cause of death is not known. In the eyes of the justice system in Sri Lanka, all MBBS qualified medical officers are deemed to be competent to conduct, report and give evidence on medico-legal examinations of patients and autopsies conducted by them, as an expert witness. However, during their undergraduate training, they may not get the opportunity to assist, nor observe, a sufficient variety of representative of cases that may be encountered in the future.

Therefore, a series of e-booklets has been prepared to better equip medical officers to handle common conditions that are likely to be encountered in day to day forensic practice. The case histories, macro and micro images are from cases conducted by Prof. Dinesh Fernando. Ms. Chaya Wickramarathne did a yeomen service in the initial designing of lay out and formatting the booklet. The compilation of the case and photographs for publication was initiated by Dr. Deshani Herath, continued by Dr. Shashika Weerasinghe and finalized by Dr. Sarangi Amarakoon.


The content herein may be used for academic purposes with due credit given.

Any clarifications, suggestions, comments or corrections are welcome.



COLOUR ATLAS OF
**FORENSIC
TRAUMATOLOGY**

Asphyxia



Asphyxia

Asphyxial deaths are caused by partial or total failure of cells to receive or utilize oxygen.

The "classic signs of asphyxia" include:

- Petechial haemorrhages in the skin of the face and the lining of the eyelids.
- Congestion and oedema of the face.
- Cyanosis (a blue discolouration) of the skin of the face.
- Right heart congestion
- Abnormal fluidity of the blood.

However, these signs are not specific to asphyxia. They can be observed in cases of congestive cardiac deaths as well. The underlying reason for the first two signs is the raised intravascular pressure in the blood vessels located in the head and neck. Cyanosis occurs due to increased amounts of deoxygenated haemoglobin in the blood. Right heart congestion and the fluidity of the blood may not necessarily point to death by asphyxia. Post-mortem fluidity of blood is not characteristic of asphyxia or any cause of death, but rather the result of a high rate of fibrinolysis that occurs in rapid deaths, possibly by high levels of catecholamines.

The abrupt increase in intravascular pressure leading to sudden over-distension and rupture of small vessels, predominantly small venules can cause pinpoint haemorrhages known as petechiae. These are most common in visceral pleurae and the epicardium, often referred to as Tardieu spots. In asphyxial deaths from strangulation, petechiae are classically seen in conjunctivae and sclera.

For forensic pathologists, petechiae on the face and neck are of paramount importance, as they indicate a need to understand their origin. It's crucial to investigate if there is any evidence supporting the idea that pressure was applied to the neck or chest, which might have led to asphyxia.

Asphyxial deaths can be classified according to the level of mechanical obstruction. Smothering, overlaying and gagging may occur at the level of the nose and mouth, whereas choking and drowning occur at the level of air passages. At the level of the neck, manual strangulation, ligature strangulation, hanging, mugging, and garrotting may occur. Other types of asphyxial deaths are traumatic asphyxia, postural asphyxia, burking and sexual asphyxia.

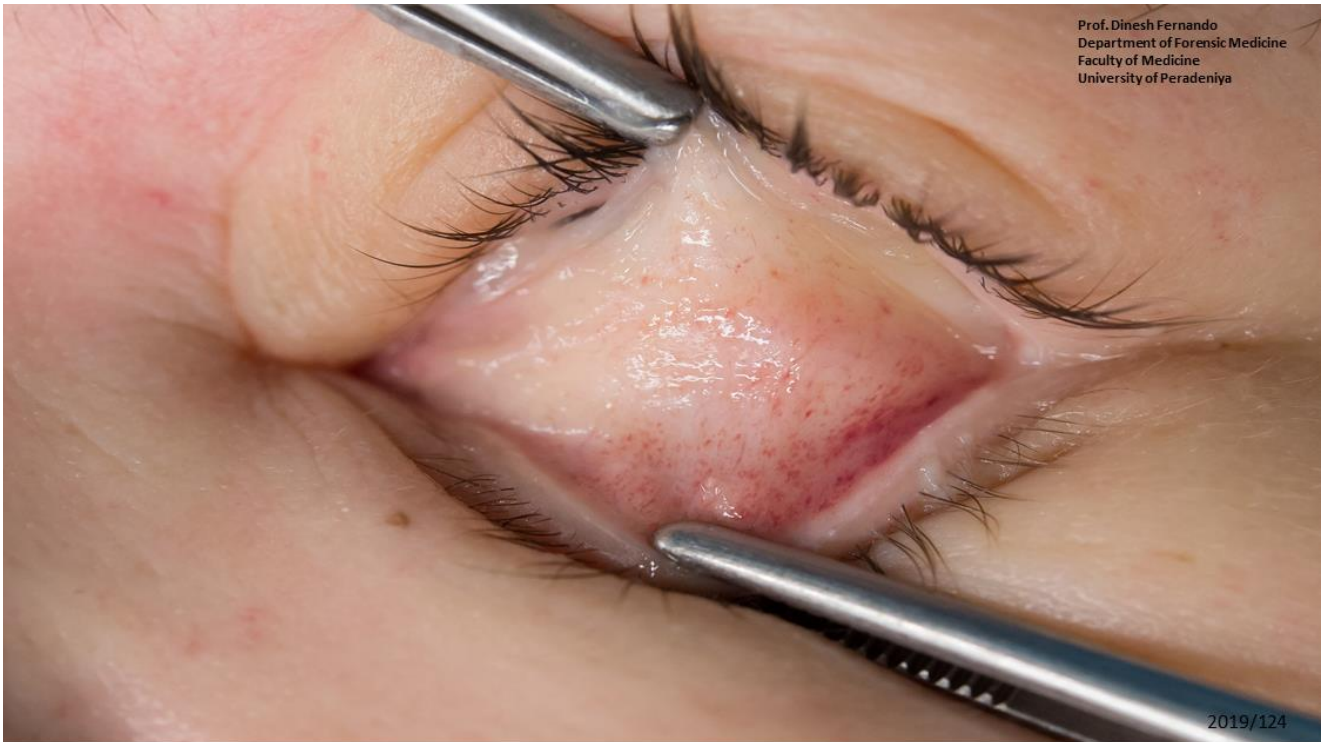

Figure 1: Mild petechial haemorrhages seen in a person who died due to manual strangulation

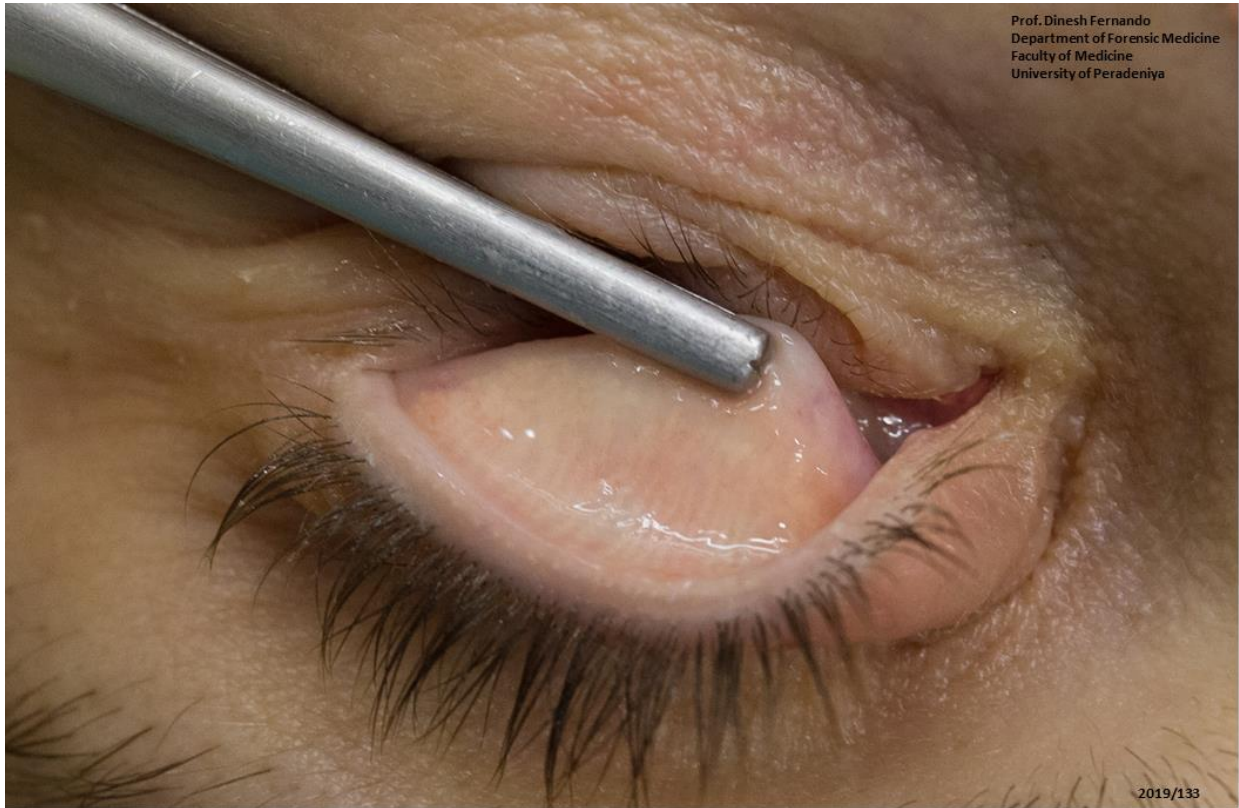


Figure 2: No petechial haemorrhages seen in a person who died due to hanging

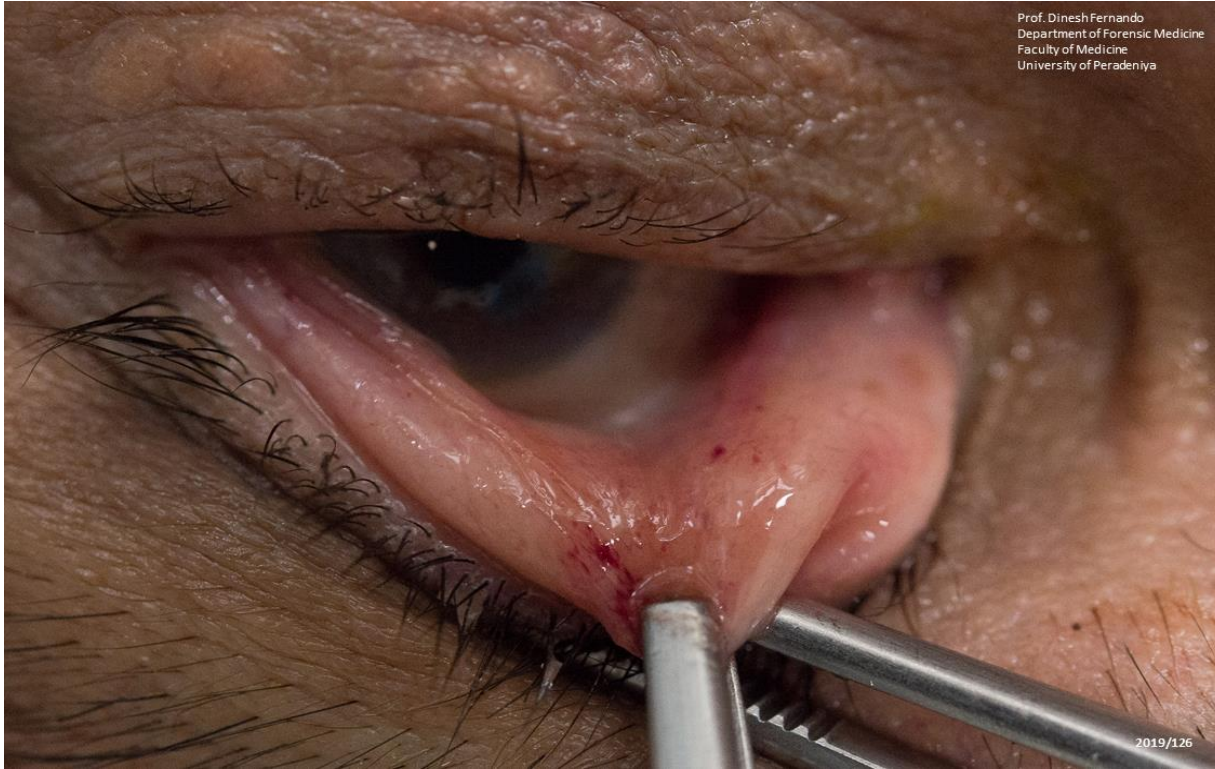


Figure 3: petechial haemorrhages in a person who died due to firearm injury to the head

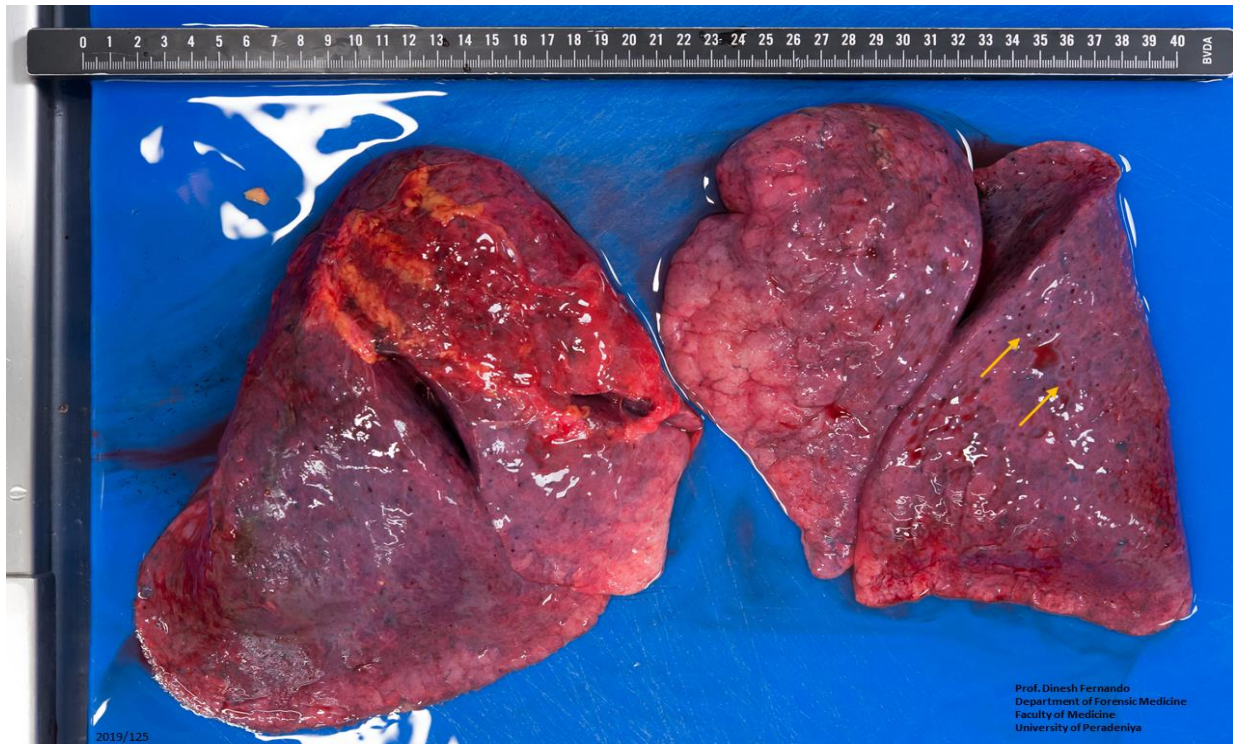



Figure 4: Tardieu spots in a person who died due to manual strangulation

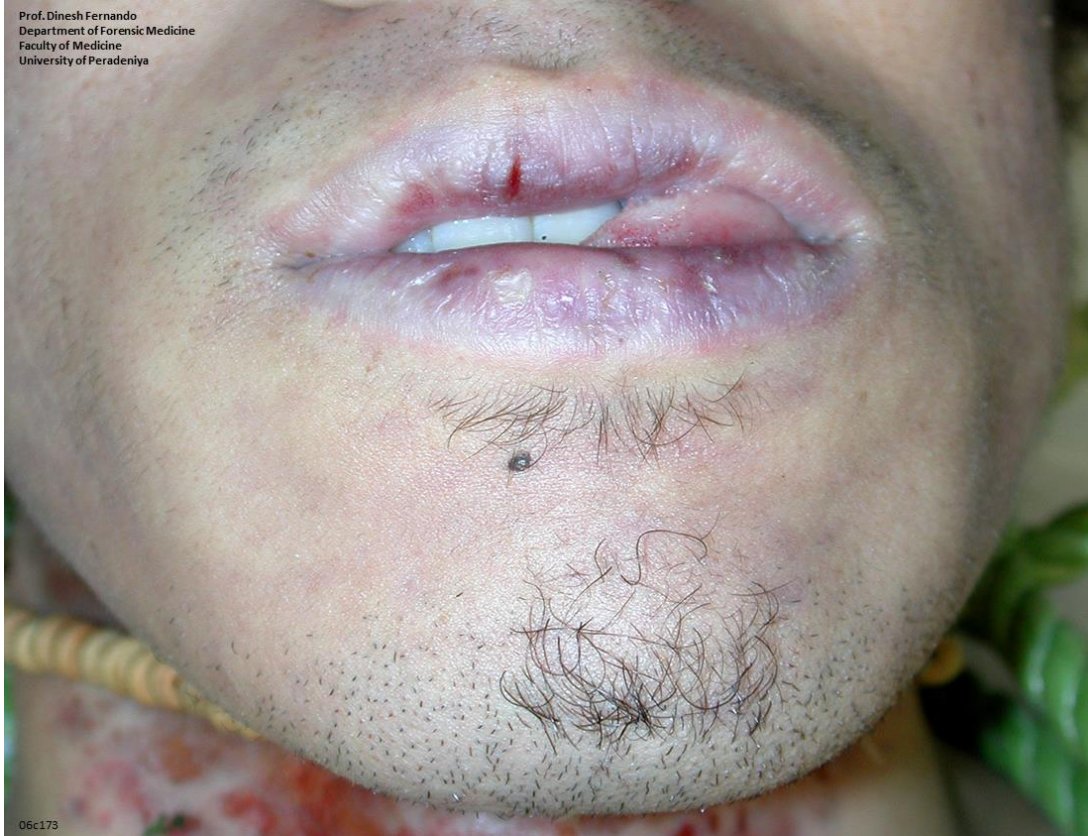

Figure 5: Cyanosis around the lips in a person who died due to hanging



Prof. Dinesh Fernando
Department of Forensic Medicine
Faculty of Medicine
University of Peradeniya


06c273

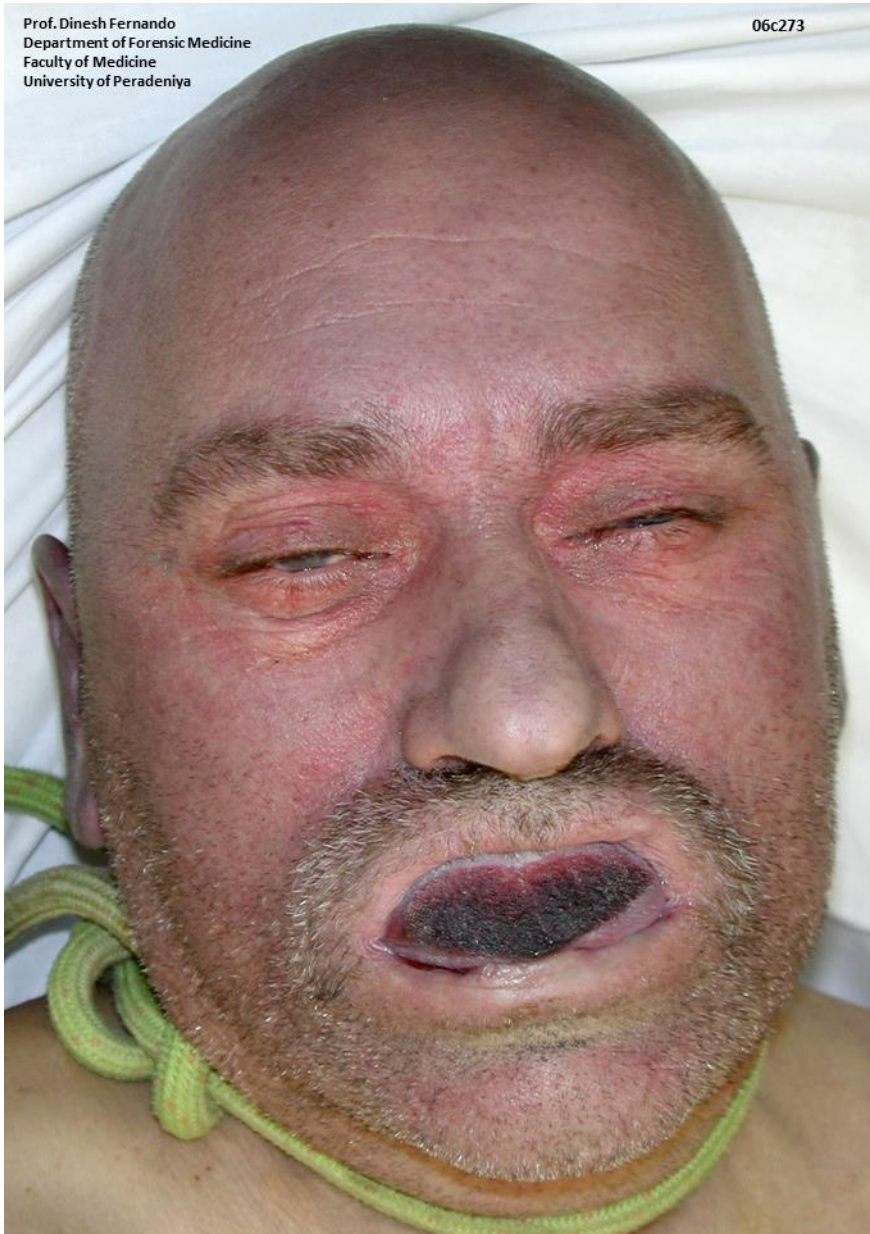

Figure 6(a): Face is congested with petechiae around the eye lids in a person who died of hanging. The tip of the tongue is clamped between teeth and is cyanosed

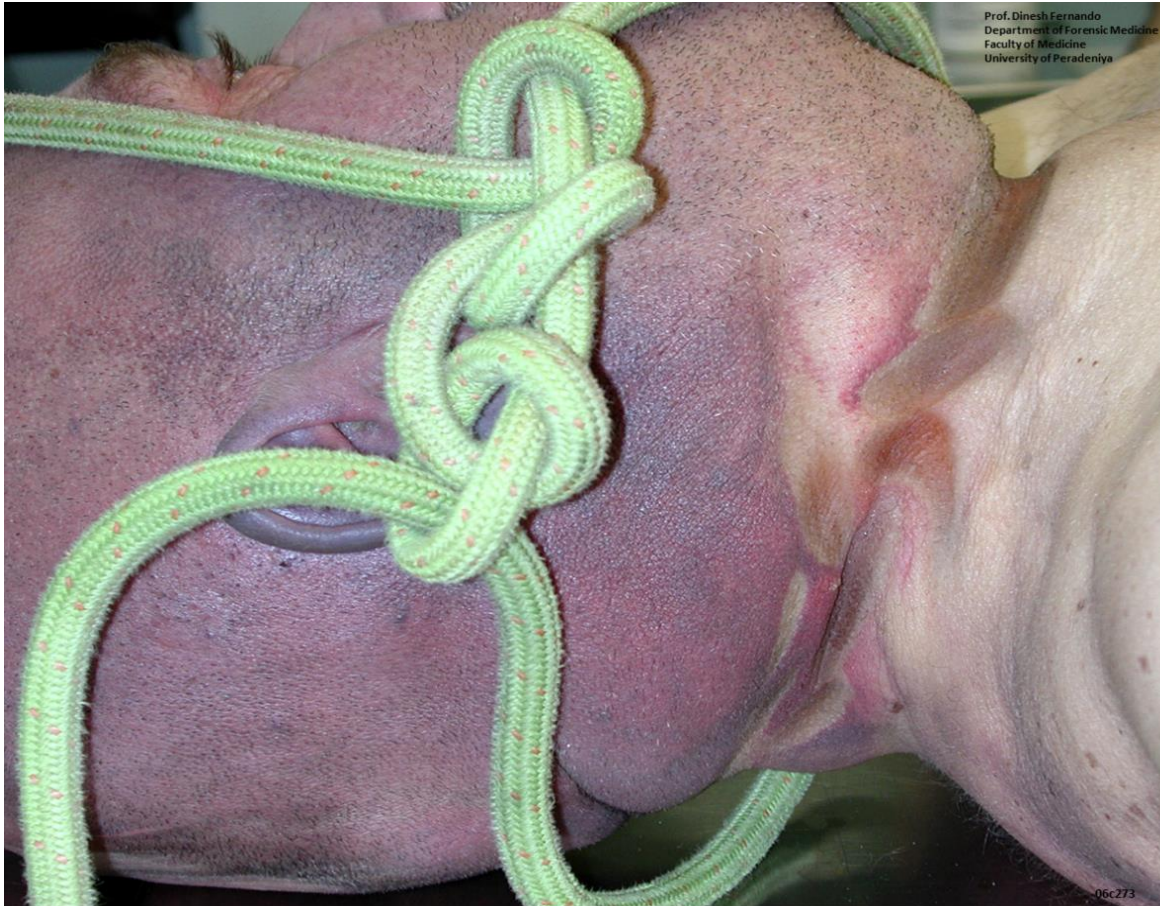

Figure 6(b): Face is extremely congested above the ligature; Note the cyanotic right ear and imprint of the knot on the skin

**Suffocation**

Suffocation is a general term used to indicate death from deprivation of oxygen, either from lack of gas in the breathable environment or from obstruction of the external air passages.

Smothering

The term smothering refers to death from mechanical occlusion of the mouth and nose, usually using agents like fabric, an impervious sheet or a hand. Occasionally it may be caused by lying face down in sand, mud, grain or flour. The circumoral and circumnasal pallor caused by passive pressure of the dependent head after death is difficult to distinguish from the pressure marks of smothering. Overlaying refers to mechanical obstruction to respiration when part of another person's body obstructs the nose and mouth.

Gagging

In gagging, a fabric or adhesive tape occludes the mouth or is thrust into the mouth to prevent speaking or shouting. While the nasal passages remain patent, air can enter, but later blockage by mucus or oedema may lead to death, usually, without any petechiae in the face or eyes.

Choking

This term refers to blockage of the internal airways, usually between the pharynx and the bifurcation of the trachea.

Death can occur due to pure hypoxia caused by occlusion of the airway. In such cases, congestion, cyanosis and petechiae may be present. But in most cases, death occurs due to neurogenic cardiac arrest in which the death occurs before any possible hypoxic manifestations.

Drowning

Drowning is a death following immersion or submersion in a fluid medium which is usually water. It may include any fluid medium. The entire body need not go underwater. Drowning can occur in shallow water when only the head/ face area goes underwater. This occurs in infants and those incapacitated due to old age, disease, intoxication and those unconscious.

Manual Strangulation

Manual strangulation is a mechanical obstruction to respiration following the constriction of the neck using the hands. A common method of homicide is most often encountered when the physical size and strength of the assailant exceeds that of the victim. It is most commonly seen in domestic homicides when a husband kills his wife, in sex-related murders when the victim is again a female, and in child killings when the killer is an adult.

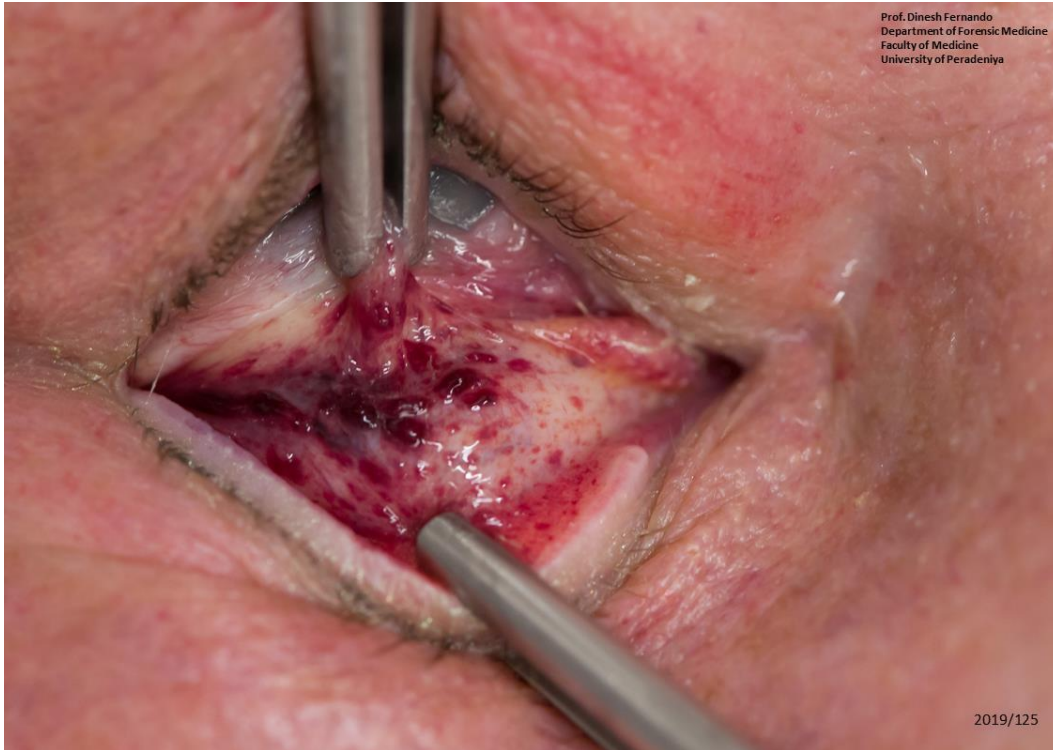


Figure 7: Florid petechial haemorrhages caused by manual strangulation



Ligature strangulation

Ligature strangulation is usually homicidal, and involves the application of pressure to the neck by an item capable of constricting the neck such as scarves, neck-ties, or cables. Typical signs include, a clear demarcation of congestion, cyanosis, and petechiae above the ligature, as well as a ligature mark on the neck. This mark may reflect the pattern of the ligature, such as that of a plaited one, and should be documented carefully with scaled photographs. Broad or soft ligatures might leave minimal signs on the skin or underlying structures.

Ligature marks usually go around the neck horizontally, but clothing or hair might cause gaps in the mark. There might be evidence of crossover or knots in the ligature. Unlike hanging, ligature strangulation does not show signs of a suspension point. Post-mortem, these marks often appear as brown parchment bands due to the drying of abraded skin. Even though accidental and suicidal ligature strangulation can happen, it is vital to approach such cases with caution until homicide is ruled out after a thorough investigation.

Hanging

Hanging is a form of ligature strangulation in which the force applied to the neck is derived from the gravitational drag of the weight of the body or part of the body.

Mugging

Originally, the term "mugging" referred specifically to a form of assault where an attacker would wrap their arm around the victim's neck from behind, applying pressure. The same arm-lock technique has been adopted by law enforcement officers as a restraining method. Unfortunately, in some cases, this method has resulted in fatal outcomes for the individual being restrained.

Garrotting

It is a method of execution or assassination, historically used in various cultures, that involves strangulation with a wire, rope, cord, or other similar tools. The wire or cord is tightened around the victim's neck, leading to death either by strangulation or severing of the spinal cord. The garrotte has been used as a method of execution in some countries, and it was notably used in Spain until the late 20th century hence it is also known as "Spanish windlass."

Traumatic asphyxia

It is caused by mechanical fixation of the chest, (therefore, also called mechanical asphyxia) and is important, both, because of its frequency in accidents and because it provides the most extreme demonstration of the 'classic signs' of asphyxia. Whereas other types of mechanical asphyxia may obstruct air entry into the lungs, 'traumatic asphyxia' acts by restricting respiratory movements, and thus, prevents inspiration. It was termed 'traumatic' because gross mechanical forces are usually the reason for the fixation of the thoracic cage.

Traumatic asphyxia occurs in two main conditions:

1. The chest and usually the abdomen are compressed by an unyielding substance or object so that chest expansion and diaphragmatic lowering are prevented.
2. Crushing in crowds or falling and being trampled in stampedes also leads to traumatic asphyxia.

Postural asphyxia

When a person remains in a certain position for an extended time, either due to being trapped or being in a drunken or drugged state, there may be a mechanical impediment to adequate respiratory movements. In addition, the normal venous return to the heart may be impaired.

Burking

Burk and Hare killed 16 people to sell the bodies to a medical faculty. Burk sits on the chest of a feeble person or one incapacitated by alcohol and closes the nose and mouth with both hands. One hand is over the nose/ mouth and the other over the chin/ upper neck. Death occurs due to a combination of traumatic asphyxia, smothering and may be palmer strangulation.

Sexual asphyxia

Autoerotic asphyxia refers to fatalities that occur during solitary sexual activity, where individuals intentionally restrict oxygen to the brain to enhance sexual arousal. The basic premise is that partial cerebral ischaemia can produce erotic hallucinations. This act is known by various names like sexual asphyxia, asphyxiophilia, and hypoxiphilia, among others. It typically involves the use of a device or restraint around the neck, leading to cerebral hypoxia. While predominantly occurring in men, there are reports of females engaging in this high-risk behaviour. Key indicators for identifying such cases include evidence of solo sexual activity, a private setting, and no signs of suicidal intent, use of unique props such as ligatures and pornography, and a malfunctioning safety device that results in death.



Bibliography

1. Di Maio DJ, Di Maio VJM. *Forensic Pathology*. 2nd ed. Boca Raton: CRC press; 2001
2. Saukko P, Knight B. *Knight's forensic pathology*. 4th ed. Boca Raton: CRC press; 2015
3. James JP, Jones R, Karch SB, Manlove J. *Simpson's Forensic Medicine*. 13th ed. London: Hodder Arnold; 2011
4. Dolinak D, Matshes EW, Lew EO. *Forensic Pathology Principles and Practice*. 1st ed. London: Elsevier Academic Press; 2005
5. Gosink PD. Autoerotic asphyxiation in a female. *Am J forensic Med Pathol*. 2000 jun;21(2):114-8
6. Richard H, Andrew L, Kim KY. Autoerotic asphyxiation: A case report. *The primary care companion for CNS disorders*. 2017;19(3)